

Management of Pancreatic Adenocarcinoma

Sung Cho MB BS, MSc FACS

Overlake Hospital Medical Center

Bellevue, WA



My Background

- Medical School: University of London, UK
- General Surgery Residency: University of Pittsburgh, PA
- Hepatobiliary Surgery Fellowship: Providence Hospital, Portland OR
- 2016-present: Overlake Hospital Medical Center, Bellevue WA

Goals of Presentation

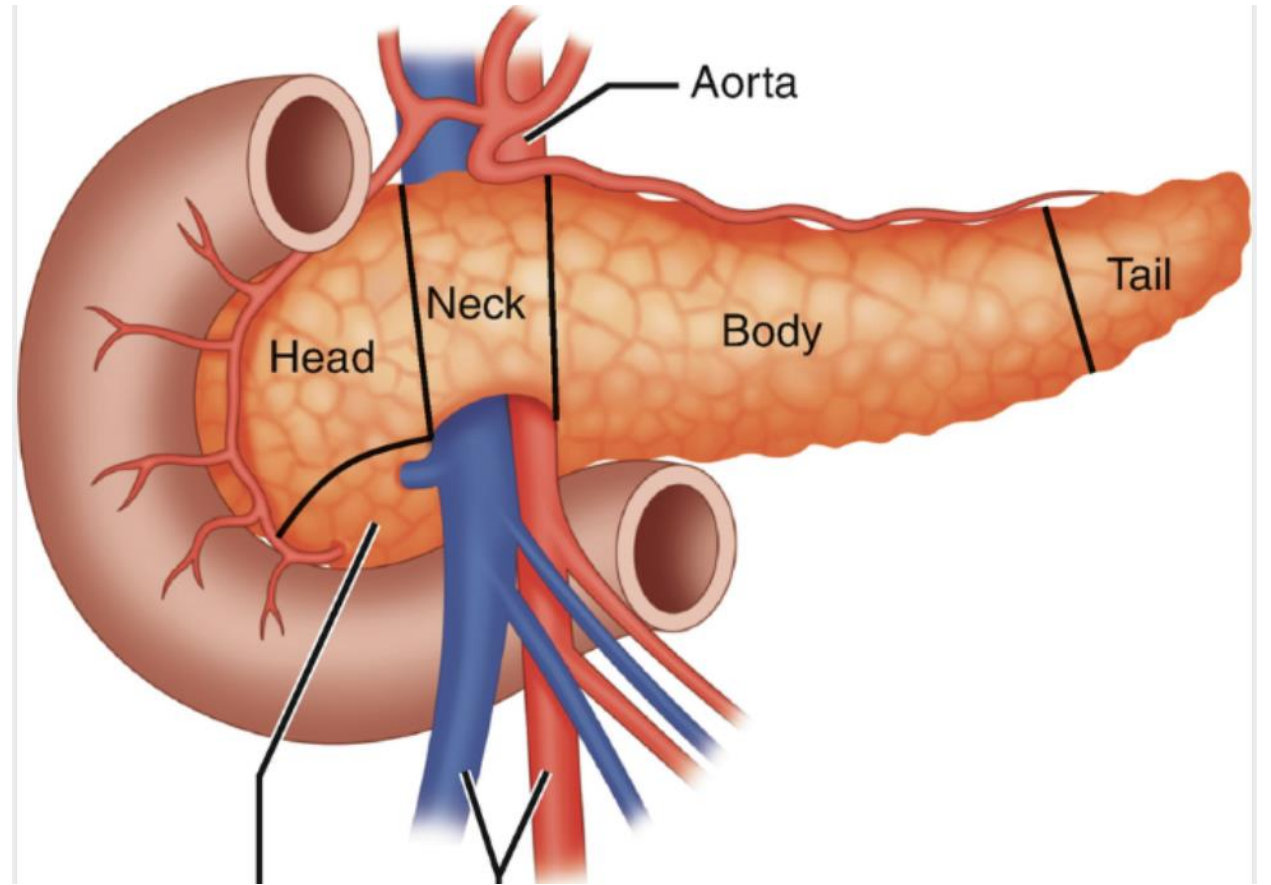
- How do you work up a patient with
 - Jaundice
 - Pancreatic mass or cyst
- How do you decide who can have surgery for pancreatic cancer?
- When and what type of chemotherapy do you give for pancreatic cancer?

Pancreatic adenocarcinoma

- 64,050 people were diagnosed with pancreatic adenocarcinoma in the USA in 2023
- 50,550 died of pancreatic adenocarcinoma in the USA
- The 4th leading cause of cancer related death
- Risk factors
 - Smoking
 - Obesity
 - Certain types of pancreatic cyst
 - Genetic mutations
 - New onset diabetes

Location of the Pancreatic Cancer

- Head – Whipple
- Neck – Whipple vs subtotal pancreatectomy
- Body and tail – distal pancreatectomy and splenectomy



A Case Study

- A 75 year old male who presented with epigastric pain
- Blood tests showed elevated LFTs.
- Cause of jaundice
 - Biliary obstruction
 - Pancreatic head mass/biliary stricture
 - Gallstones
 - Medical
 - Liver cirrhosis
 - Drug related/autoimmune hepatitis etc
- What test do you order next?

BUN	9.0
Creatinine	0.82
eGFR	>=90

Comment: eGFR calculation is based on the 2021 CKD-EPI equation that estimates kidney function without a race variable as recommended by the NKF-ASN task force.

Sodium	140
Potassium	4.0
Chloride	107
CO2	27
Anion Gap	6
Calcium	8.7
Total Protein	5.7 Low
Albumin	3.5
Bilirubin Total	4.8 High
Alkaline Phosphatase	370 High
ALT (SGPT)	334 High
AST (SGOT)	153 High

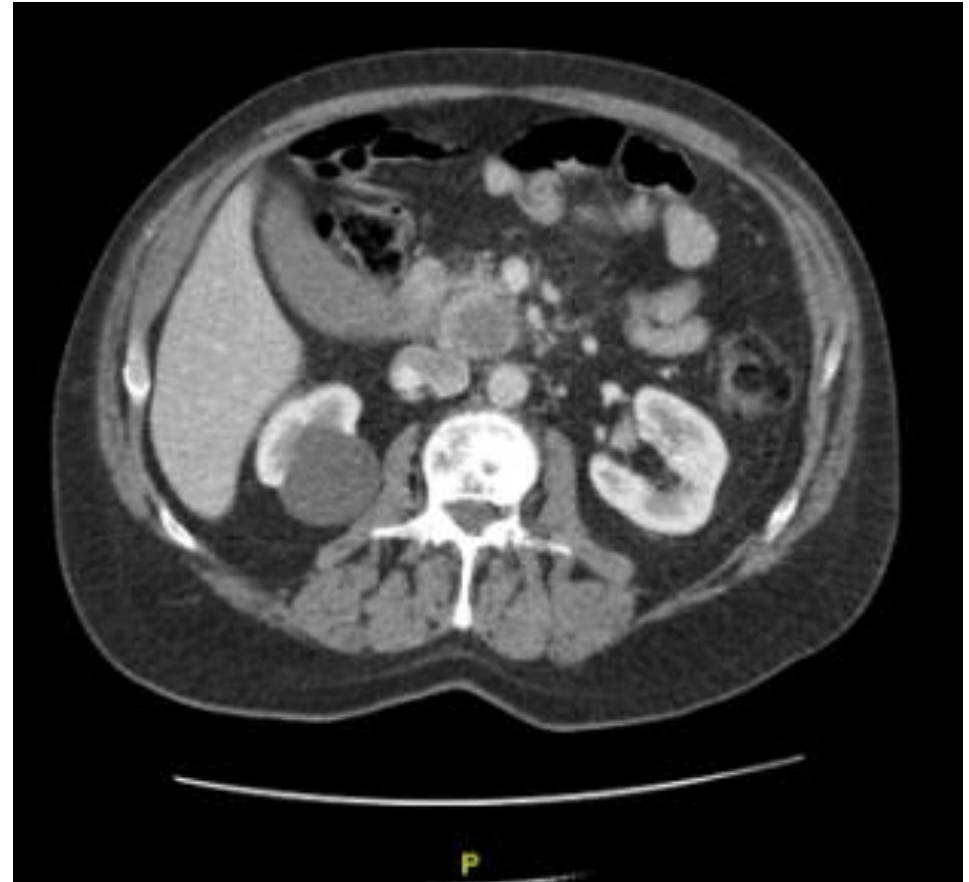Liver ultrasound for jaundice. What to look for?

- Dilated bile duct?
- Gallstone in the gallbladder/the bile duct?
 - Normal sized bile duct
 - ?medical cause
 - Dilated bile duct (>6-7 mm in diameter)
 - Likely due to distal obstruction
 - If suspecting gallstone in the bile duct
 - order MRCP
 - If suspecting pancreatic mass
 - CT scan pancreas protocol
- Refer to GI and HPB surgeon for pancreatic mass/bile duct stricture
- Liver cirrhosis on USS?
 - Refer to GI/hepatologist

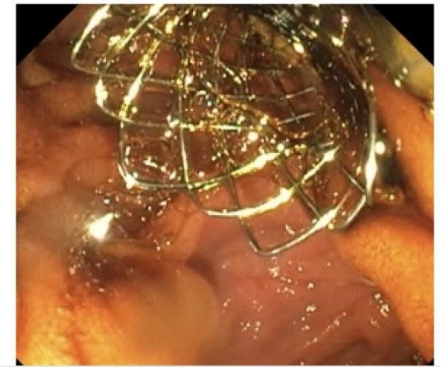
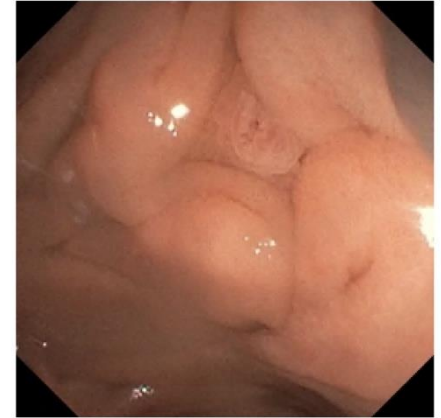
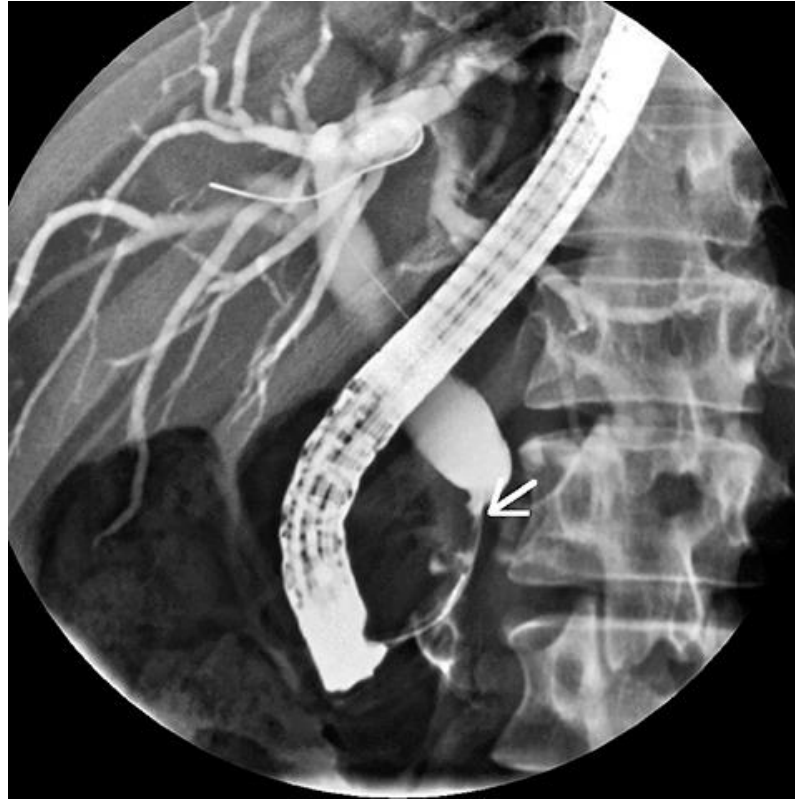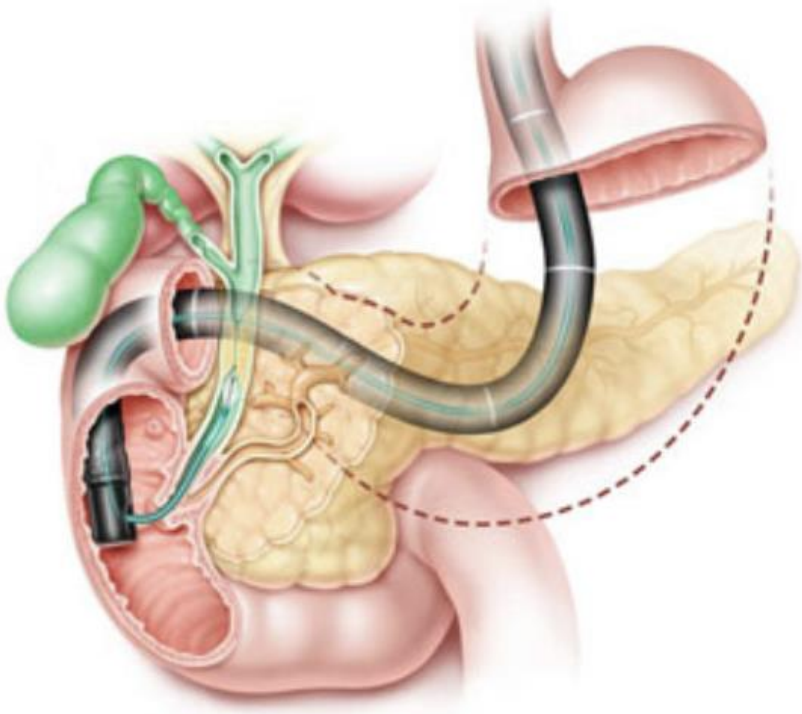
CT scan showed a mass in the uncinate process of the pancreas

What test do we need next?

- The next test to order is not MRCP.
- Referral to GI for endoscopic ultrasound and ERCP
- Referral to HPB surgeon



ERCP for biliary drainage



Biliary Drainage Options

- ERCP

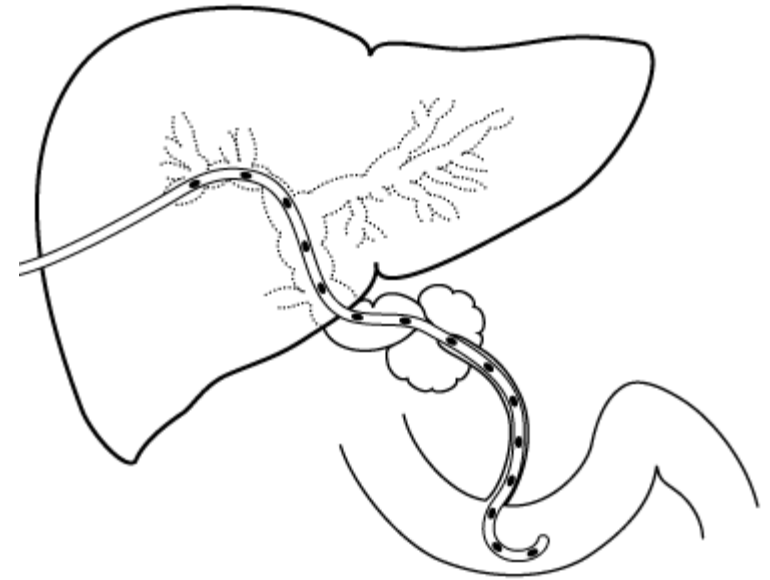
 - Types of biliary stent

 - plastic

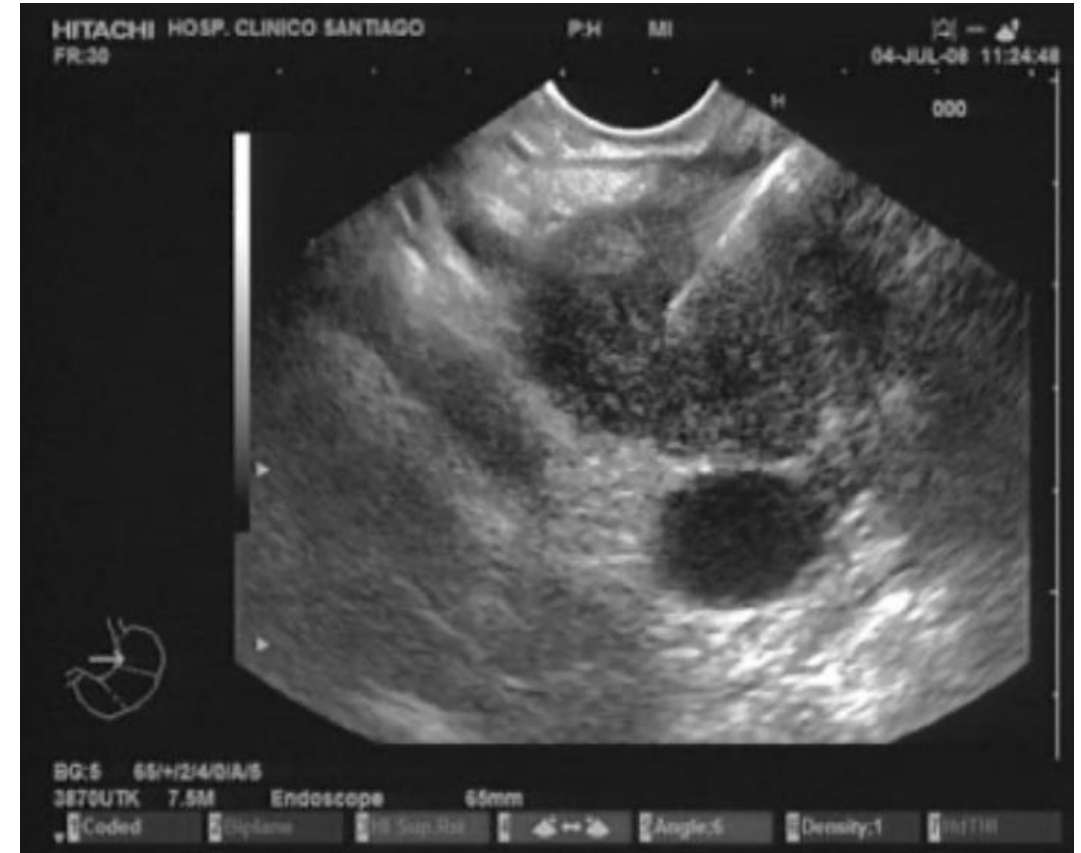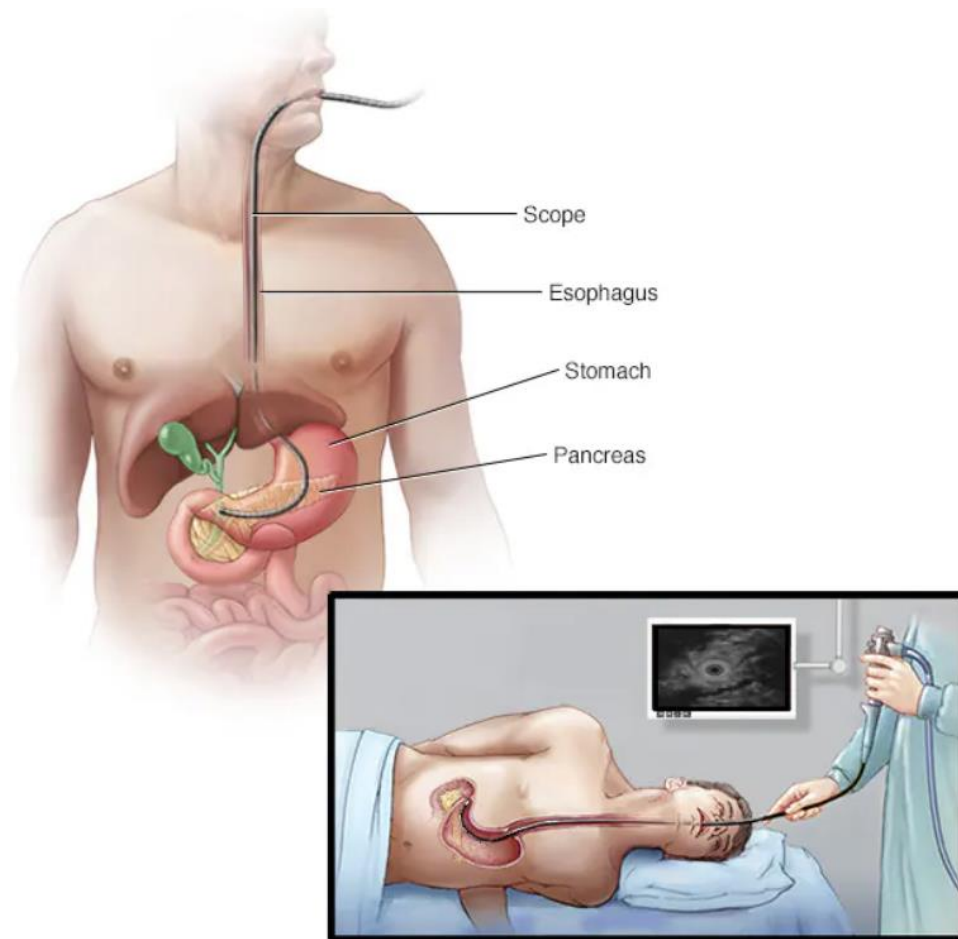
 - metallic (bare vs covered)

- Self expanding metallic stent
preferable to plastic stent

- If ERCP un-successful, consult IR for
percutaneous biliary drainage (PBD)



Endoscopic Ultrasound



Endoscopic ultrasound showed:-

Pancreas:

In the head of the pancreas/uncinate process there was a 4.1 x 2.8 cm hypoechoic, heterogeneous, ill-defined mass. The mass obstructed the common bile duct and the pancreatic duct. There was endosonographic evidence of invasion into the wall of the duodenum. There was no endosonographic evidence of vascular invasion. A Cook 25-gauge echoendoscope needle was obtained and advanced to the endoscope. After confirming the absence of any intervening vessels using Doppler ultrasonography, 6 passes were made into the mass with return of material. Preliminary review by the pathologist of a portion of the samples obtained were read as being positive for atypical cells suspicious for carcinoma. Immediately adjacent to the mass was an oval, hypoechoic, homogeneous, well-defined lymph node measuring 12.7 mm in maximal longitudinal diameter.

Final Diagnosis





Pancreatic head mass, EUS-FNA/biopsy:

- Positive for malignant cells, consistent with pancreatic ductal carcinoma with both adeno- and squamous features.

Newly diagnosed pancreatic head adenocarcinoma – what to do next?

- Staging
 - CT chest
 - CT abdomen pancreas protocol
 - +/- CT PET scan
- Serum Ca 19 9 level
- Referral to medical oncology
- Referral to hepatobiliary surgeon
- How do you decide whether a patient can have surgery?



Stage I & II	Resectable	Tumor may touch blood vessels.	 A red, circular cross-section of a blood vessel with a black, irregular tumor mass touching its outer edge.
Stage III	Borderline Resectable	Tumor abuts the blood vessels. <i>The tumor is in contact with less than 180° (less than half) of the blood vessel.</i>	 A red, circular cross-section of a blood vessel with a black, irregular tumor mass touching its outer edge over less than half of its circumference.
	Locally Advanced <ul style="list-style-type: none">• Type A• Type B	Tumor encases the blood vessels. <i>The tumor is in contact with more than 180° (over half) of the blood vessel.</i>	 A red, circular cross-section of a blood vessel with a black, irregular tumor mass completely encircling it.
Stage IV	Metastasized	Tumor has spread beyond the pancreas.	 An anatomical illustration of a human torso showing the pancreas, liver, and stomach. Black spots representing metastases are shown on the liver and in the abdominal cavity.

Treatment plan depends on resectability

- Resectable pancreatic cancer (no vascular involvement by tumor)
 - Upfront surgery
 - Neoadjuvant chemotherapy and then surgery
- Borderline resectable cancer (partial vascular involvement)
 - Neoadjuvant chemotherapy
 - Surgery
 - Adjuvant chemotherapy
- Locally advanced cancer (>180 degree vascular involvement)
 - Chemotherapy +/- radiation treatment
- Metastatic cancer
 - Systemic chemotherapy
 - Palliative treatment (e.g. celiac axis block)

NCCN guideline for resectability

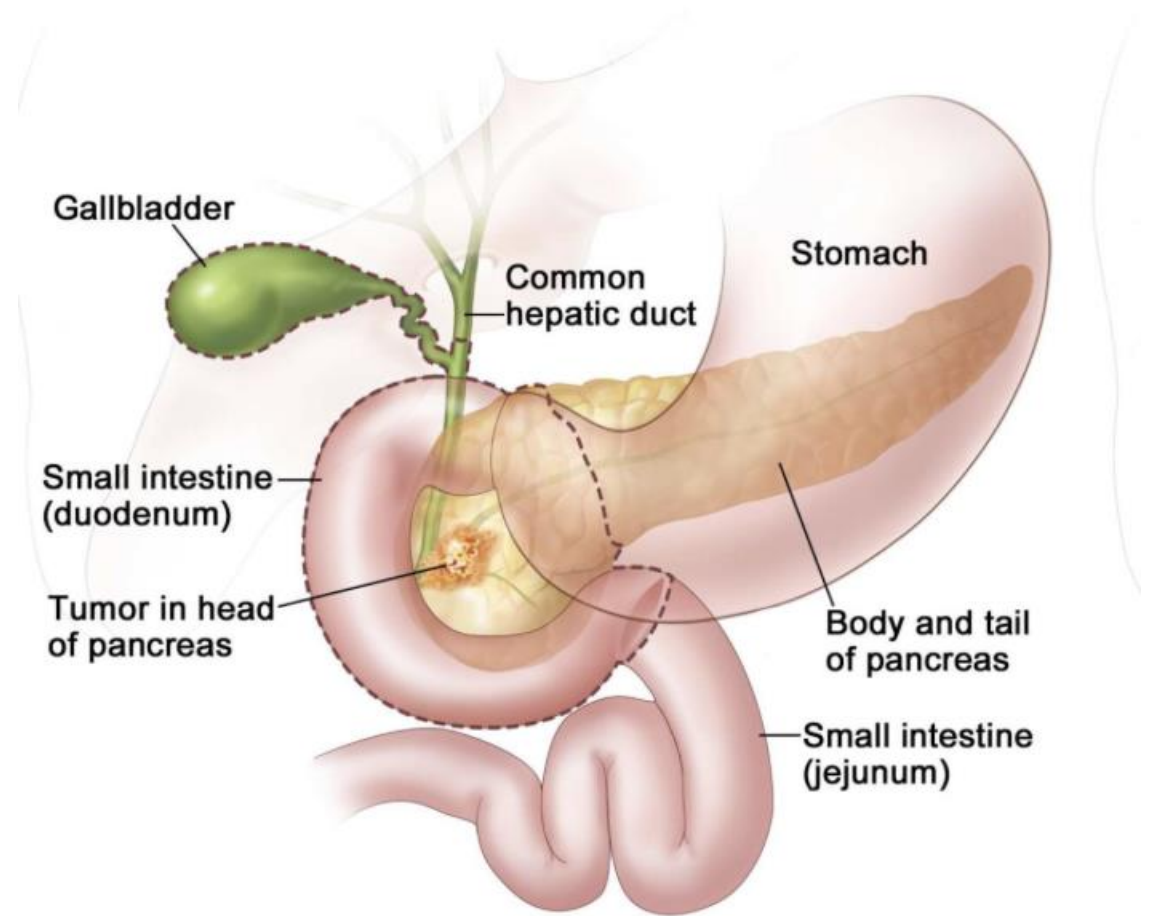
CRITERIA DEFINING RESECTABILITY STATUS AT DIAGNOSIS^a

- Decisions about resectability status should be made in consensus at multidisciplinary meetings/discussions.

Resectability Status	Arterial	Venous
Resectable	<ul style="list-style-type: none"> • No arterial tumor contact (celiac axis [CA], superior mesenteric artery [SMA], or common hepatic artery [CHA]). 	<ul style="list-style-type: none"> • No tumor contact with the superior mesenteric vein (SMV) or portal vein (PV) or $\leq 180^\circ$ contact without vein contour irregularity.
Borderline Resectable ^b	<p>Pancreatic head/uncinate process:</p> <ul style="list-style-type: none"> • Solid tumor contact with CHA without extension to CA or hepatic artery bifurcation allowing for safe and complete resection and reconstruction. • Solid tumor contact with the SMA of $\leq 180^\circ$. • Solid tumor contact with variant arterial anatomy (eg, accessory right hepatic artery, replaced right hepatic artery, replaced CHA, and the origin of replaced or accessory artery) and the presence and degree of tumor contact should be noted if present, as it may affect surgical planning. <p>Pancreatic body/tail:</p> <ul style="list-style-type: none"> • Solid tumor contact with the CA of $\leq 180^\circ$. 	<ul style="list-style-type: none"> • Solid tumor contact with the SMV or PV of $>180^\circ$, contact of $\leq 180^\circ$ with contour irregularity of the vein or thrombosis of the vein but with suitable vessel proximal and distal to the site of involvement allowing for safe and complete resection and vein reconstruction. • Solid tumor contact with the inferior vena cava (IVC).
Locally Advanced ^{b,c,d}	<p>Head/uncinate process:</p> <ul style="list-style-type: none"> • Solid tumor contact $>180^\circ$ with the SMA or CA. <p>Pancreatic body/tail:</p> <ul style="list-style-type: none"> • Solid tumor contact of $>180^\circ$ with the SMA or CA. • Solid tumor contact with the CA and aortic involvement. 	<ul style="list-style-type: none"> • Not currently amenable to resection and primary reconstruction due to complete occlusion of SMV/PV

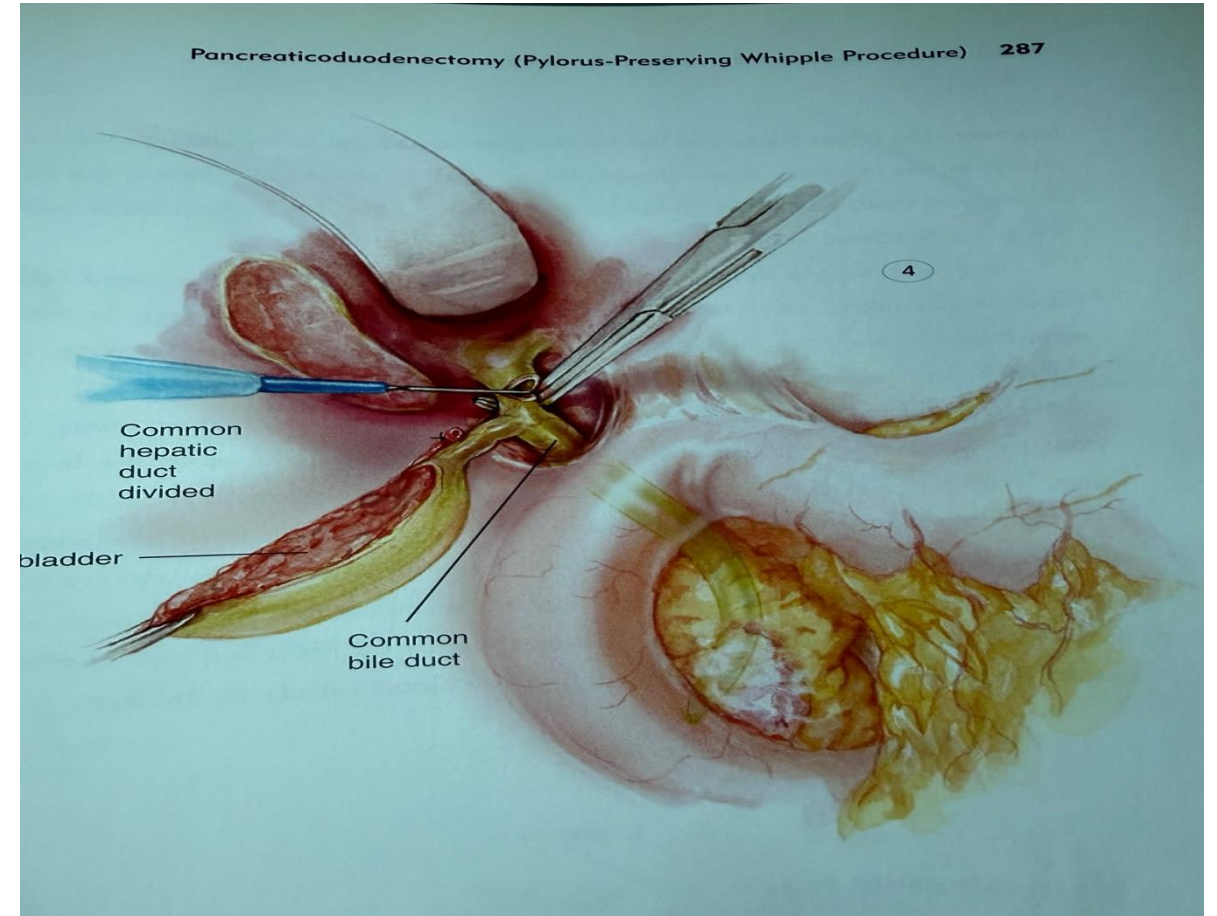
Whipple procedure

- For pancreatic head cancer
- Involves resection of
 - Pancreatic head
 - Duodenum and proximal jejunum
 - Bile duct
 - Gallbladder

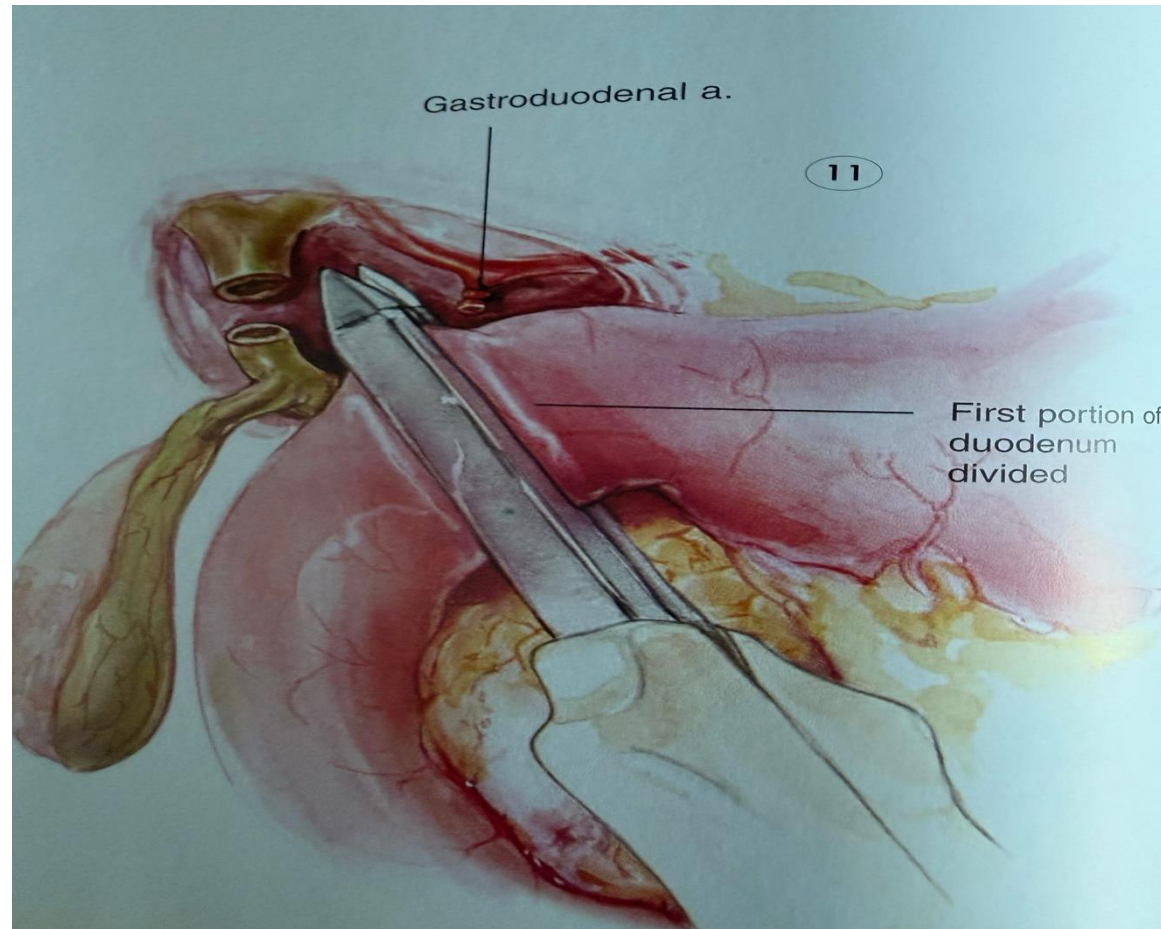


Portal dissection

- Bile duct resection
- Cholecystectomy
- Ligation of gastroduodenal artery

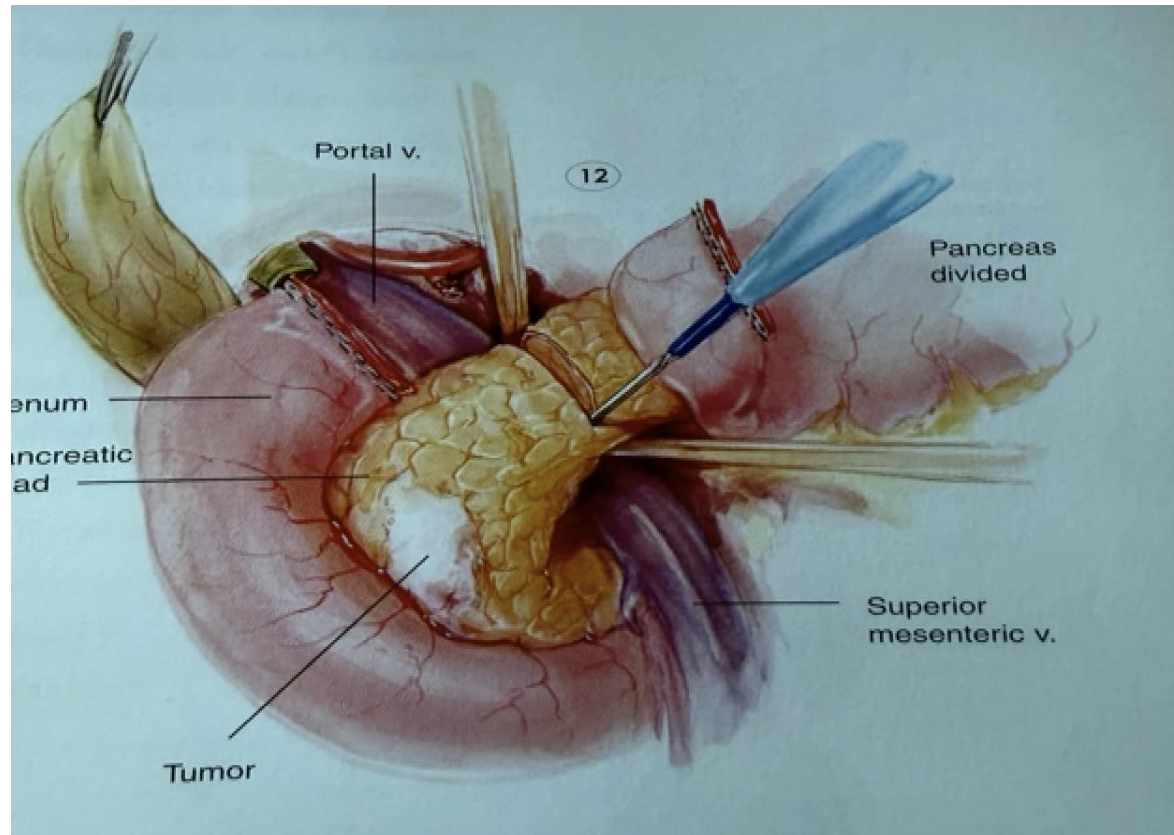


Division of the duodenum



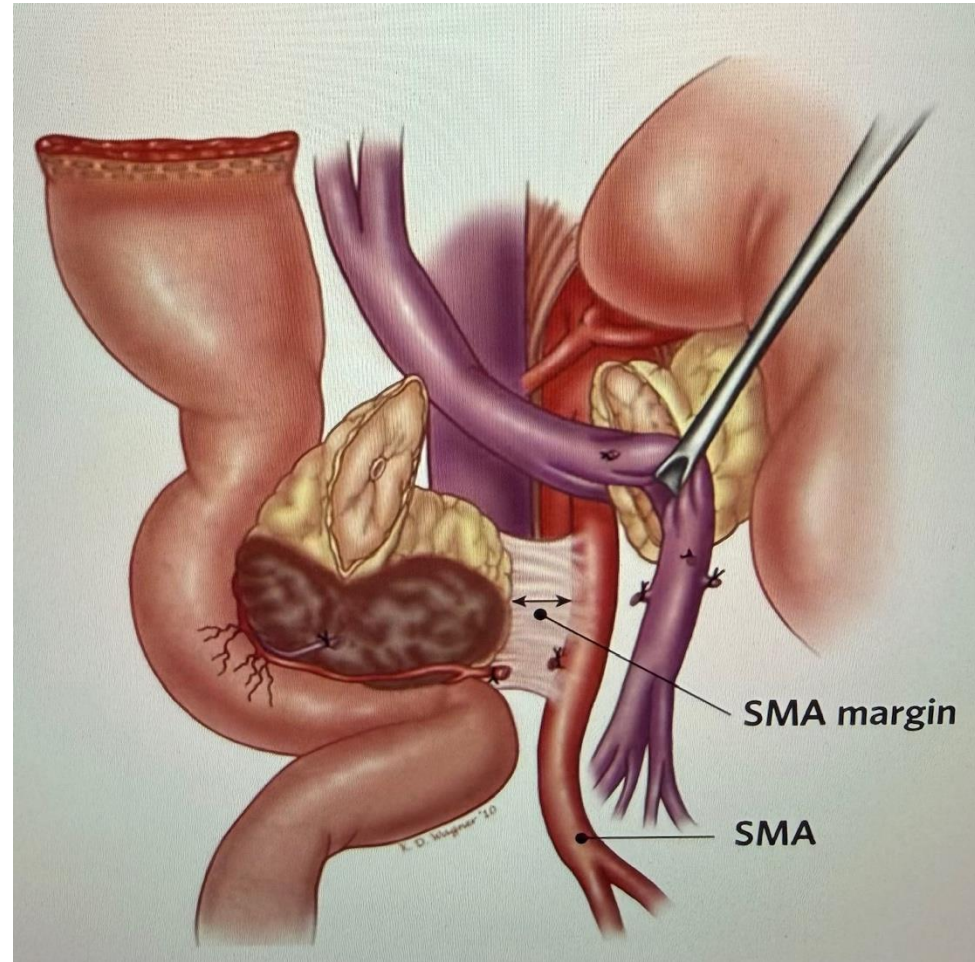
Cameron, Sandone, Atlas of GI Surgery

Division of the pancreatic neck

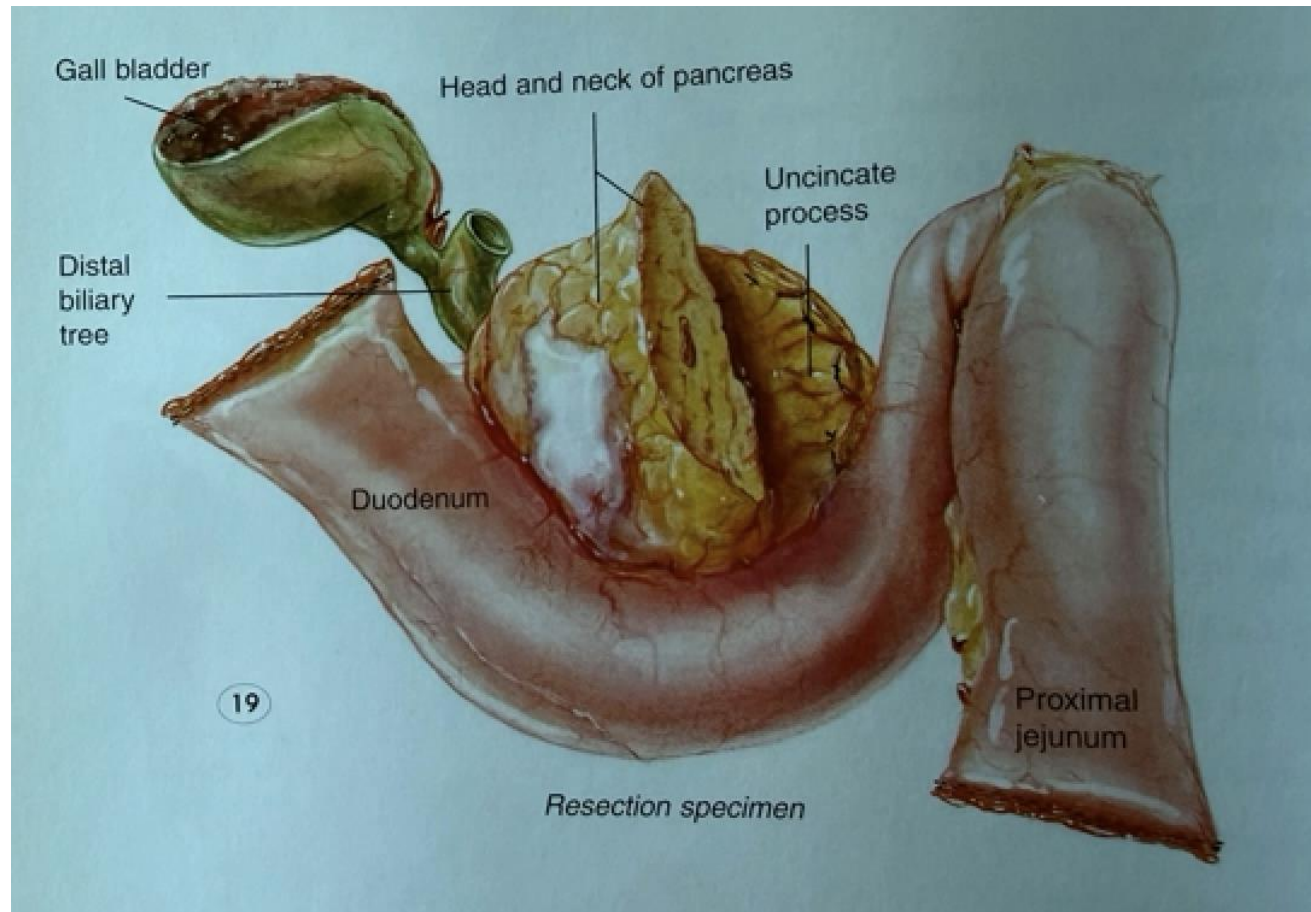


Cameron, Sandone, Atlas of GI Surgery

Uncinate process dissection

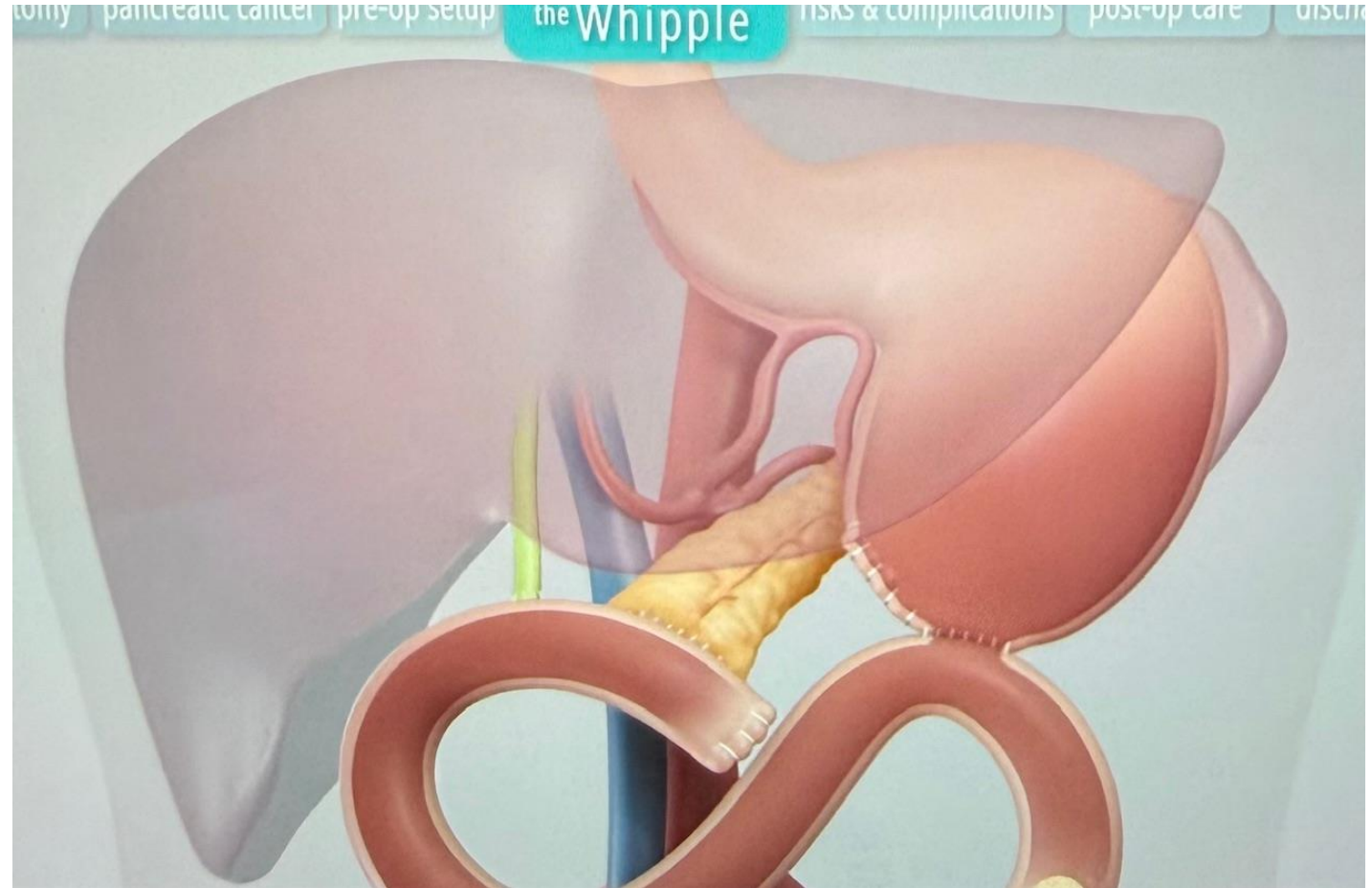


Whipple Resection Specimen



Reconstruction of Whipple procedure

- Three anastomoses made
 - Bile duct
 - Pancreatic remnant
 - Stomach



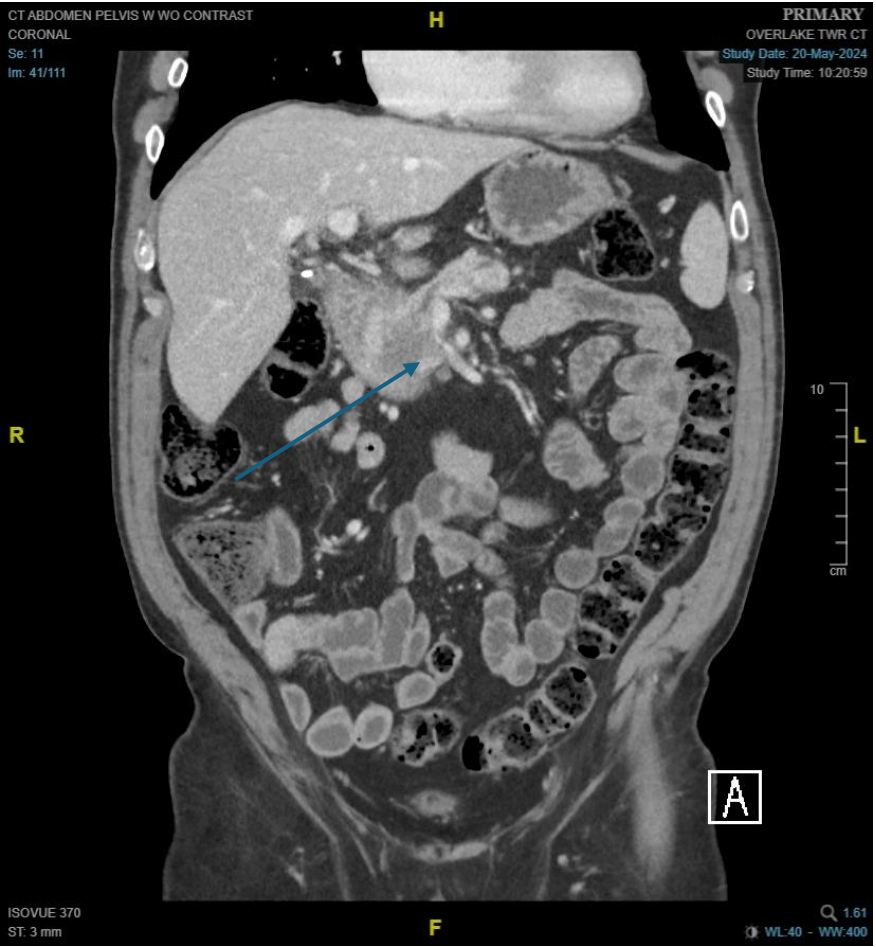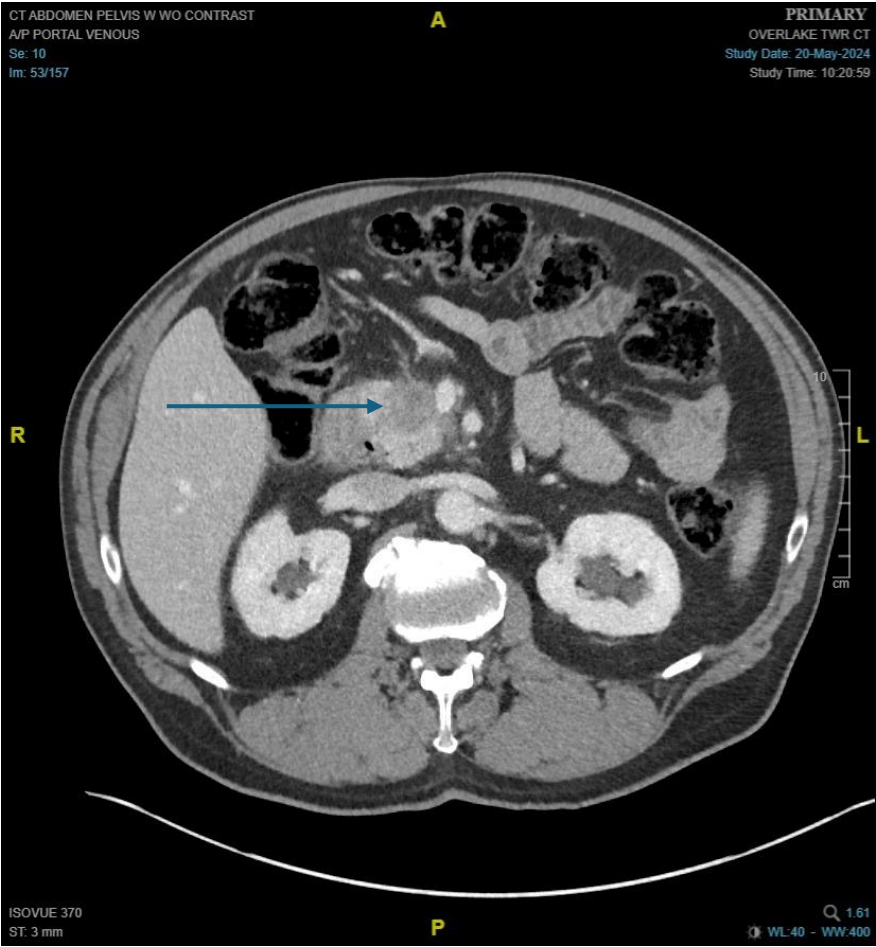
Potential Postop Complications

- Early postop period
 - Pancreatic leak
 - Delayed gastric emptying
 - Bleeding from gastroduodenal artery
- Late postop period
 - 5-10% risk of diabetes
 - Hernia
 - Marginal ulcer bleeding (@ gastrojejunostomy anastomosis)
 - cholangitis

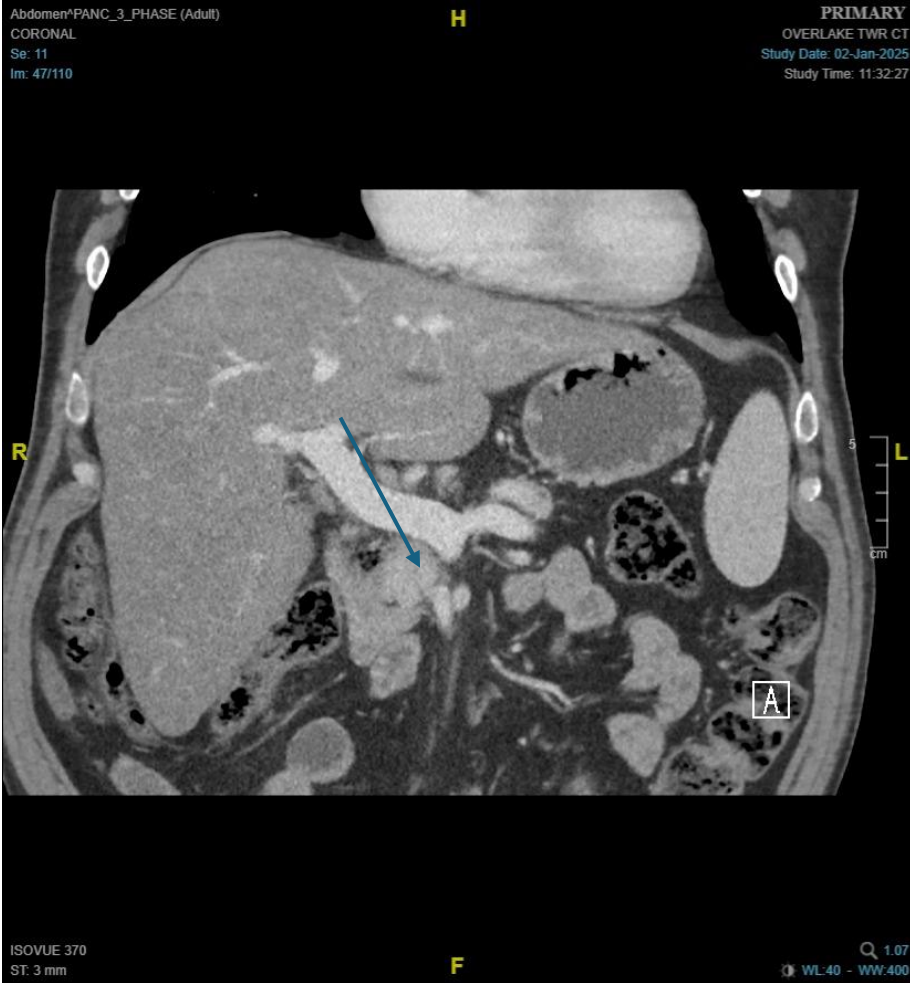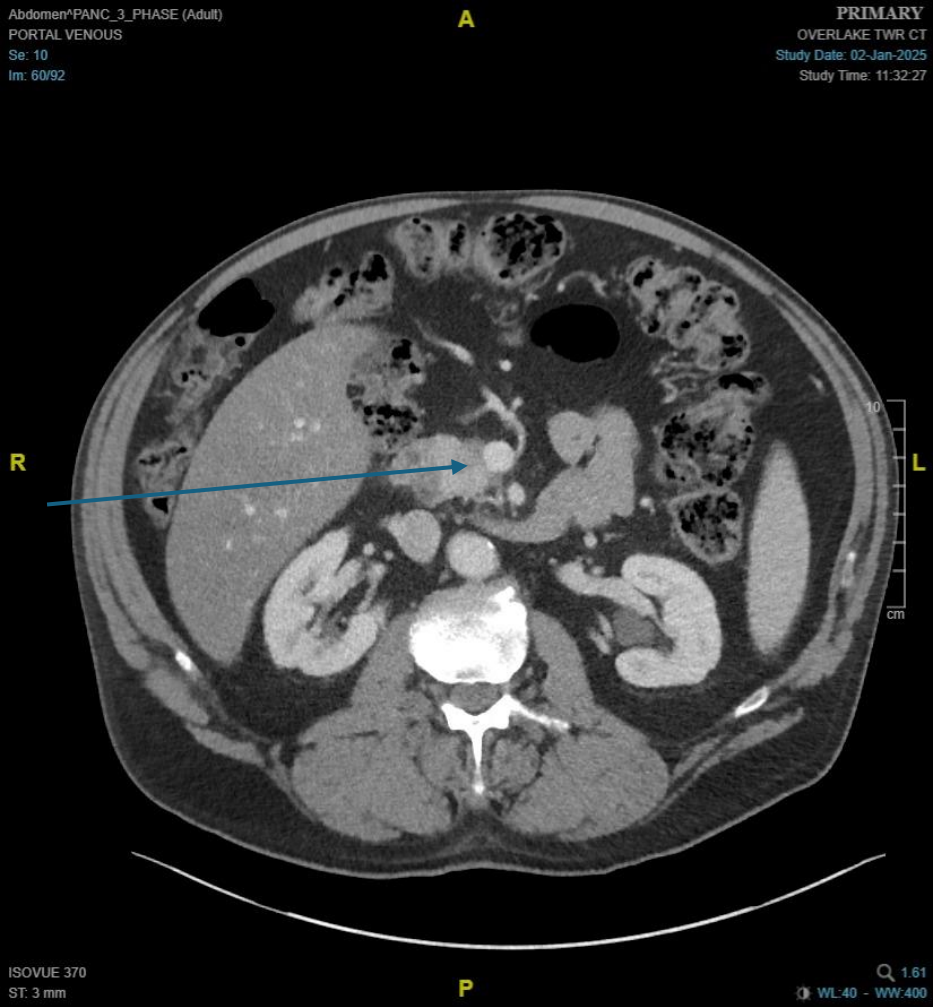
Borderline resectable tumor

- Less than 180 degree involvement of SMA/hepatic artery
- Less than 180 degree involvement of SMV/portal vein
- Give neoadjuvant chemotherapy for 3-4 months first and reassess with a new CT scan

64 yo male with pancreatic head adenocarcinoma



After neoadjuvant chemotherapy (FOLFIRINOX)



Pathology Report of Whipple Specimen

Tumor Site:

Pancreatic head

Histologic Type:

Ductal adenocarcinoma (NOS)

Histologic Grade (applies to ductal carcinoma only):

G2-G3, moderately to poorly differentiated

Tumor Size:

Estimated 2 cm in greatest dimension

Site(s) Involved by Direct Tumor Extension:

Confined to pancreas

Treatment Effect:

Present, with residual cancer showing evident tumor regression, but more than single cells or rare small groups of cancer cells (partial response, score

2) Lymphovascular Invasion:

Not identified

Perineural Invasion:

Not identified

Margin Status for Invasive Carcinoma:

All margins negative for invasive carcinoma

Margin Status for Dysplasia and Intraepithelial Neoplasia:

All margins negative for intraepithelial neoplasia

Regional Lymph Node Status:

Regional lymph nodes present

All regional lymph nodes negative for tumor

Number of lymph nodes examined: 13

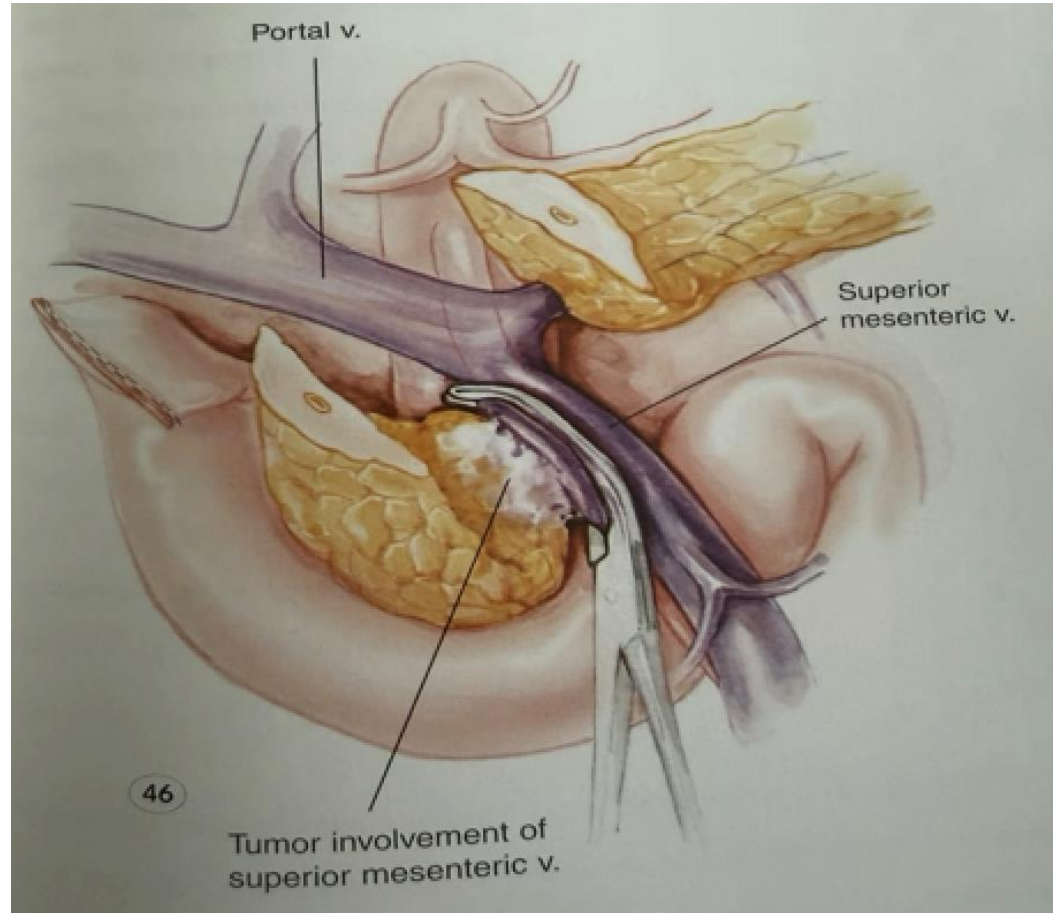
Distant Site(s) Involved:

Not applicable

Pathologic Stage Classification (pTNM, AJCC 8th Edition):

ypT1c ypN0

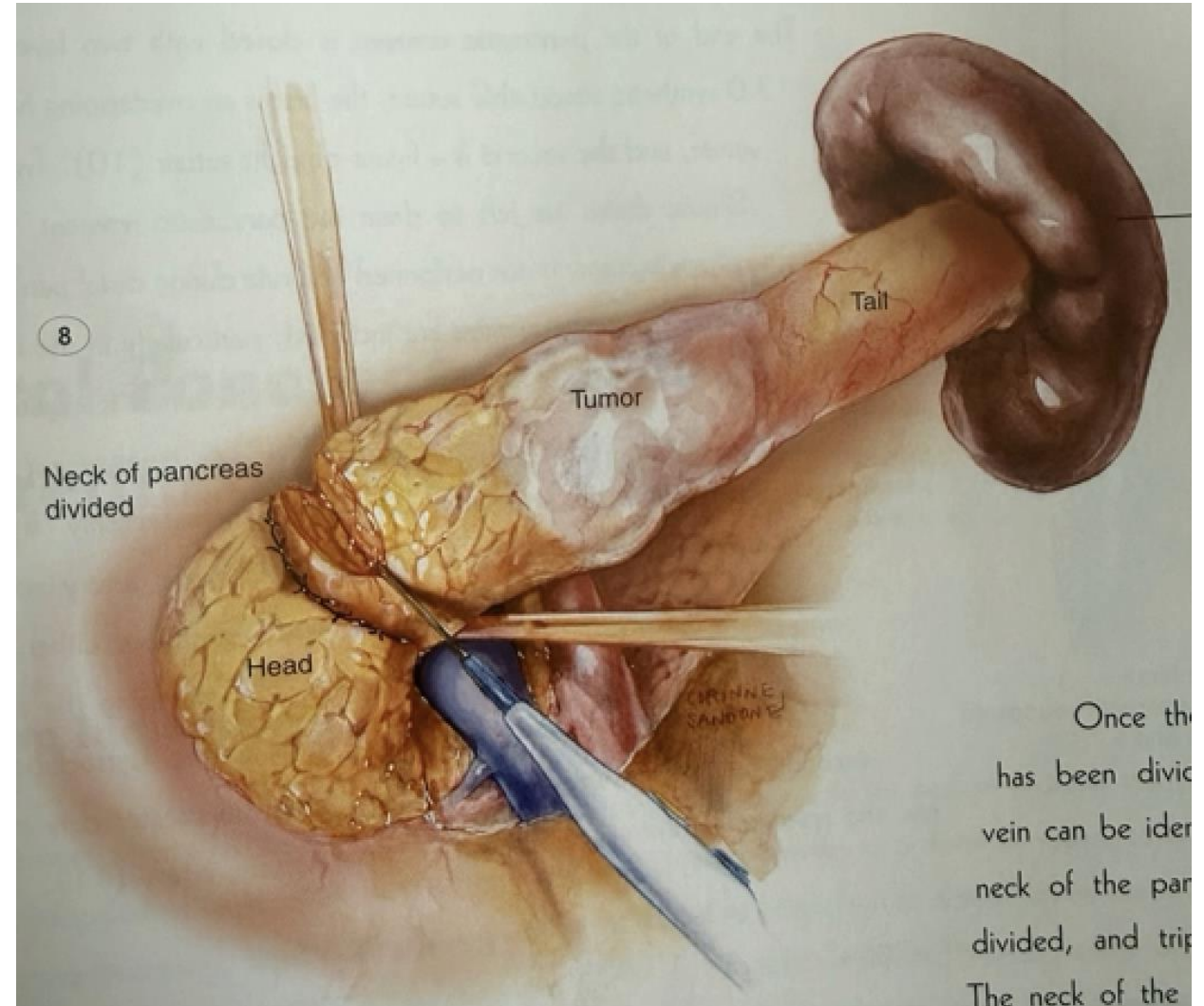
En bloc Resection of SMV during Whipple



Cameron, Sandone, Atlas of GI Surgery

Distal Pancreatectomy and Splenectomy

- For cancer in the body and tail of the pancreas
- Celiac artery, SMA artery and portal vein/SMV involvement determines resectability
- Splenic artery and vein can be involved and still a surgical candidate.
- The stomach, the transverse colon can be resected en bloc



Who gets chemotherapy?

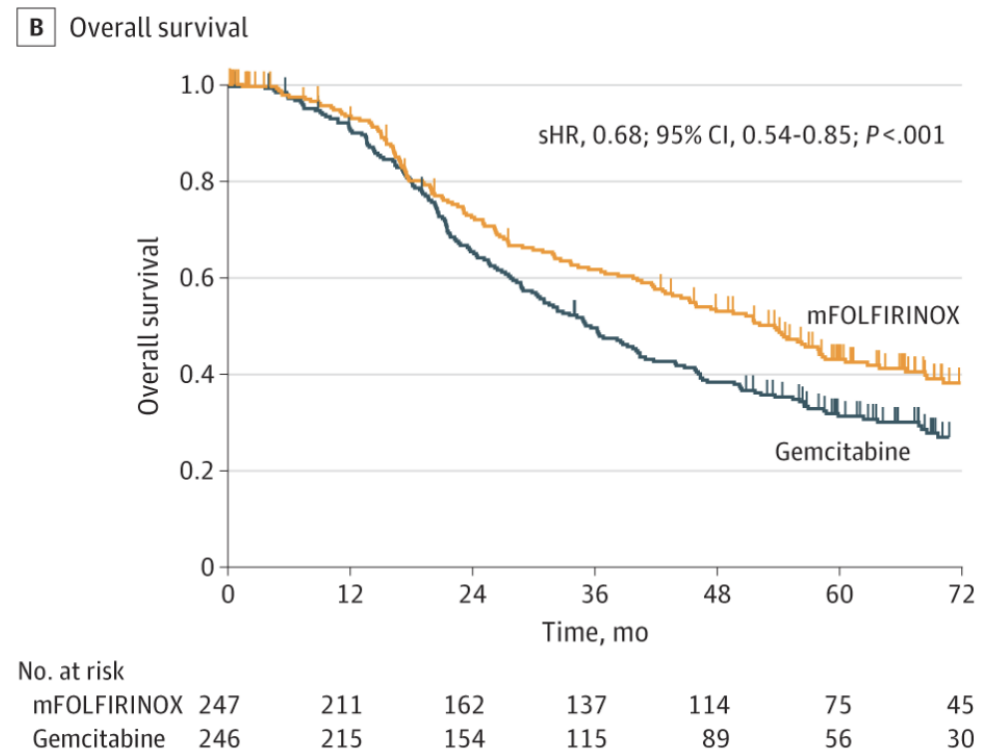
- Before surgery (neoadjuvant)
 - Borderline resectable
- After surgery (adjuvant)
 - Resectable
- Definitive treatment without surgery
 - Locally advanced
 - Stage 4

Types of chemotherapy regimen

- Fluorouracil + leucovorin + irinotecan + oxaliplatin
- Gemcitabine + albumin-bound paclitaxel
- Gemcitabine alone

mFOLFIRINOX chemotherapy after curative surgery for pancreatic cancer

- 5 year overall survival
 - mFOLFIRINOX: 43.2%
 - Gemcitabine: 31.4%

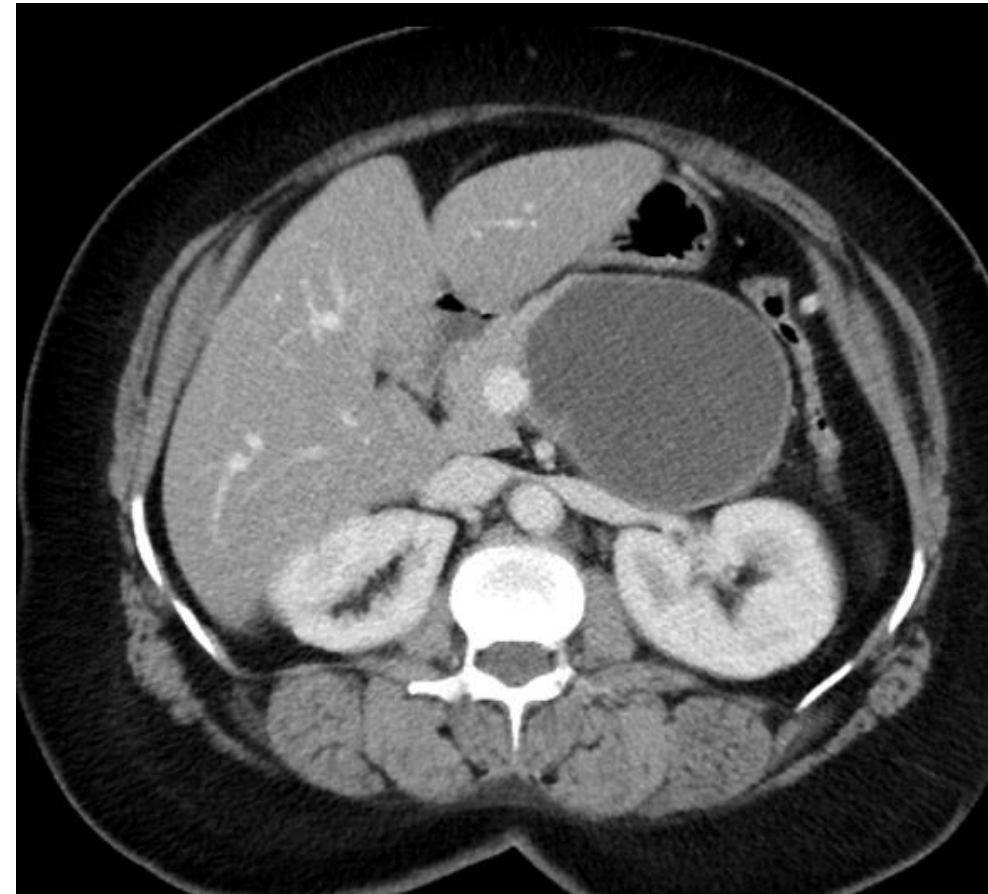


Other pancreatic findings on imaging studies

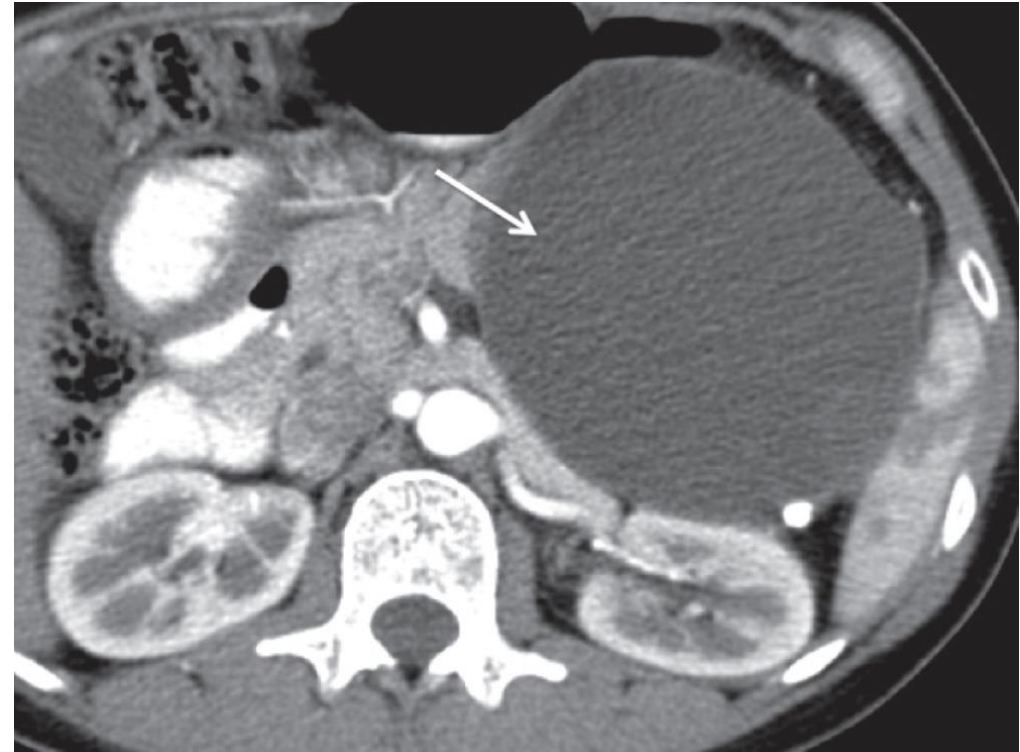
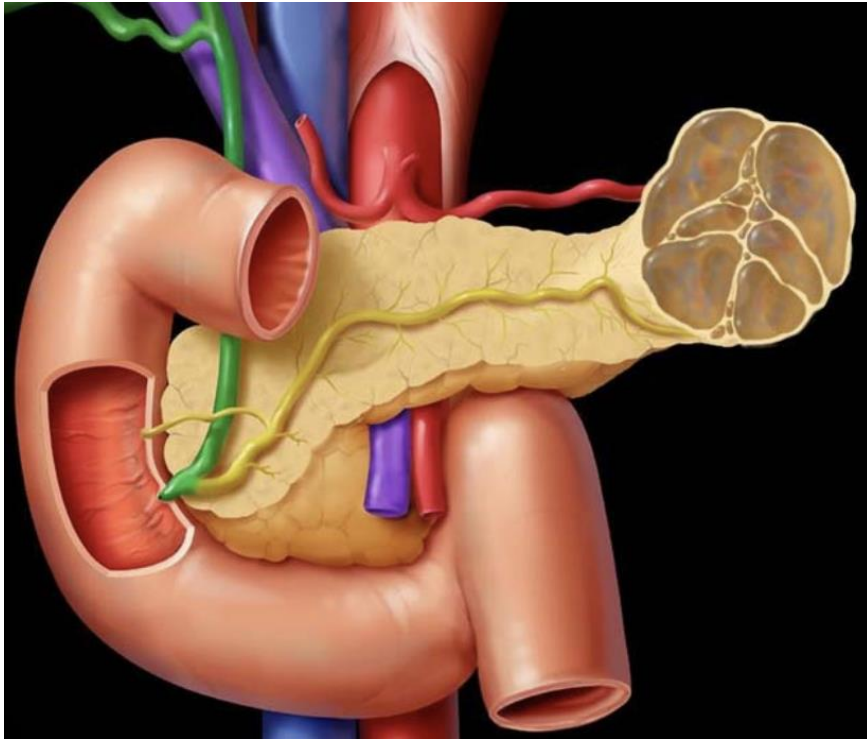
- Pancreatic cyst
 - Mucinous cyst
 - Serous cyst
 - Pancreatic pseudocyst
- Dilated pancreatic duct
 - IPMN
 - Pancreatic head mass obstructing pancreatic duct
 - Chronic pancreatitis

Pancreatic cyst

- Endoscopic ultrasound evaluation and cyst fluid analysis determines the type
 - Mucinous cyst
 - Mucin filled
 - Serous cyst
 - Water filled
 - Pancreatic pseudocyst
 - Hx of pancreatitis in the past



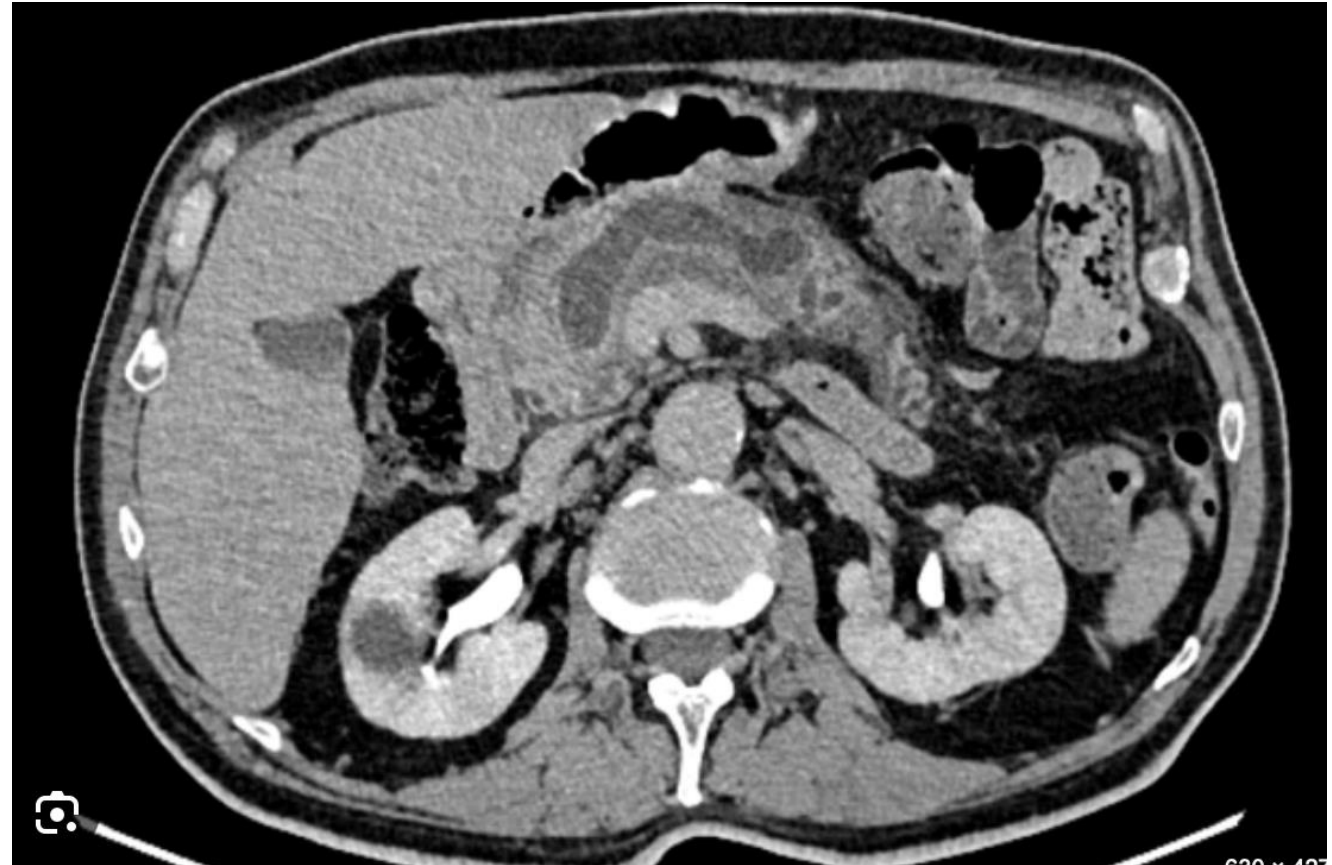
Mucinous Cystic Neoplasm of the Pancreas



- Usually occurs in the body or tail of the pancreas
- Young/middle aged female
- Mucin in the cyst. Cyst CEA level > 200
- It has malignant potential and an indication for surgery

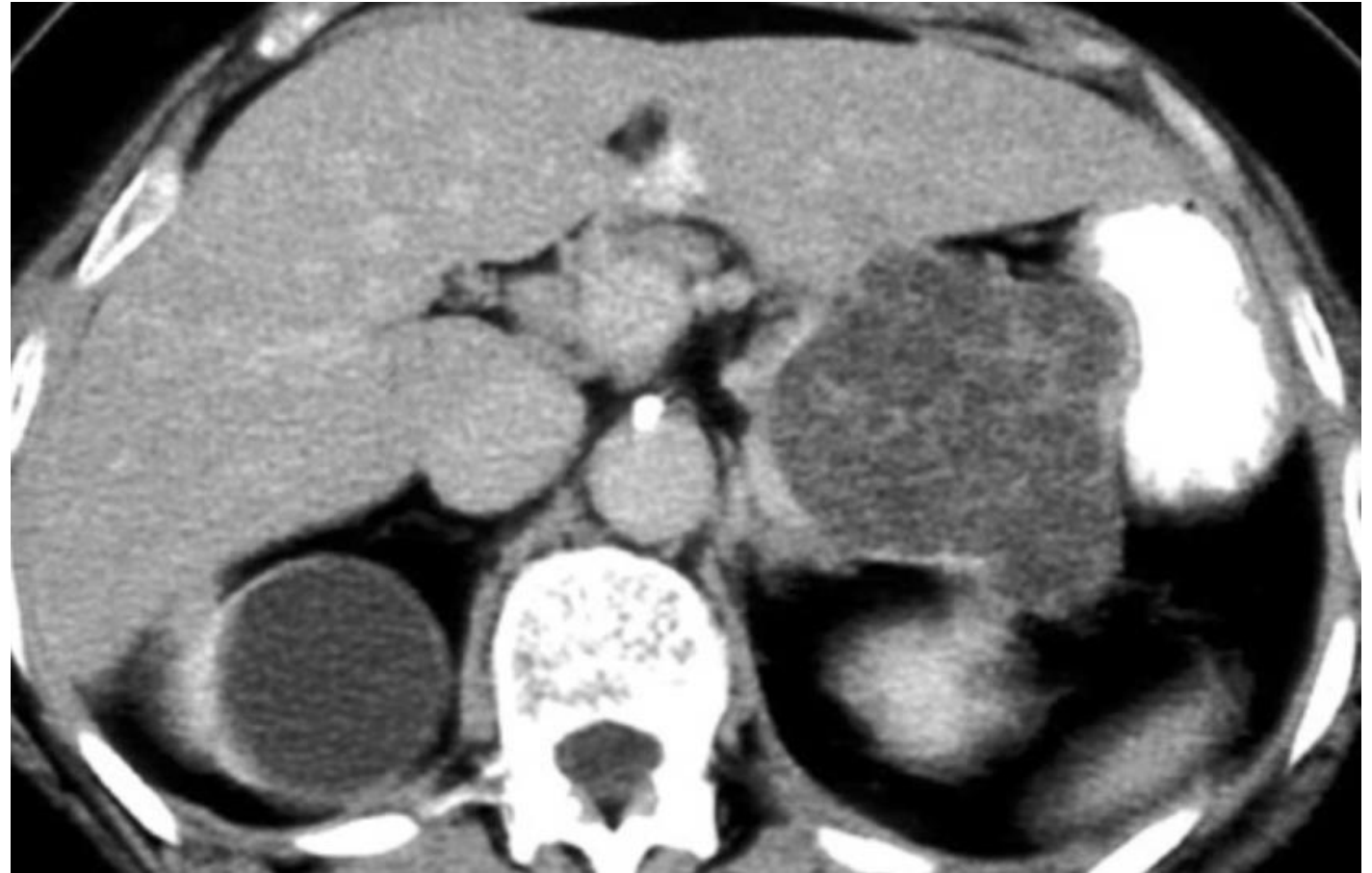IPMN (intraductal papillary mucinous neoplasm)

- Main duct IPMN
 - Dilated pancreatic duct
 - High risk for malignancy
 - Usually an indication for surgery
- Side branch IPMN
 - Normal diameter pancreatic duct
 - Lower risk of malignancy potential
 - Intervene if
 - Mural nodule
 - >3 cm in size
 - Increase in size
- Mixed duct type IPMN

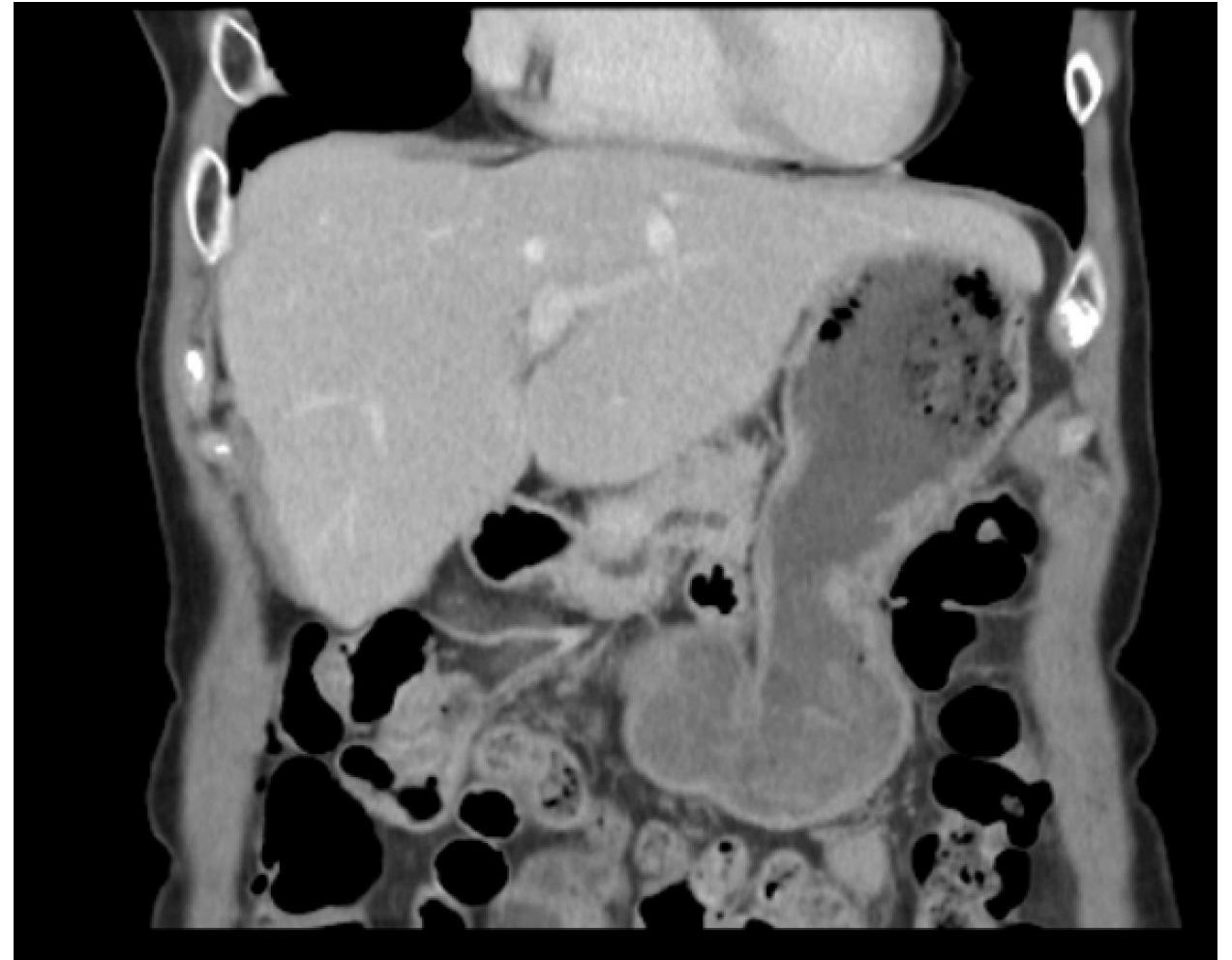
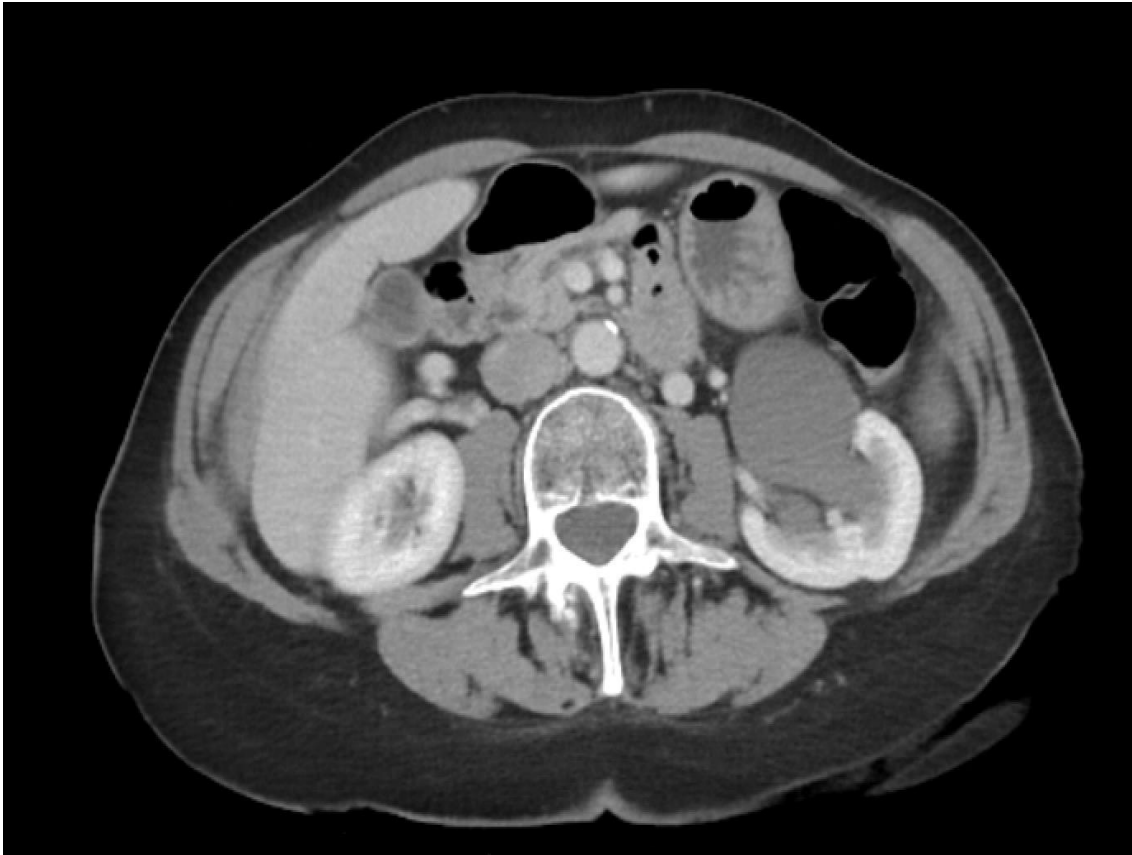


Benign Pancreatic Cyst

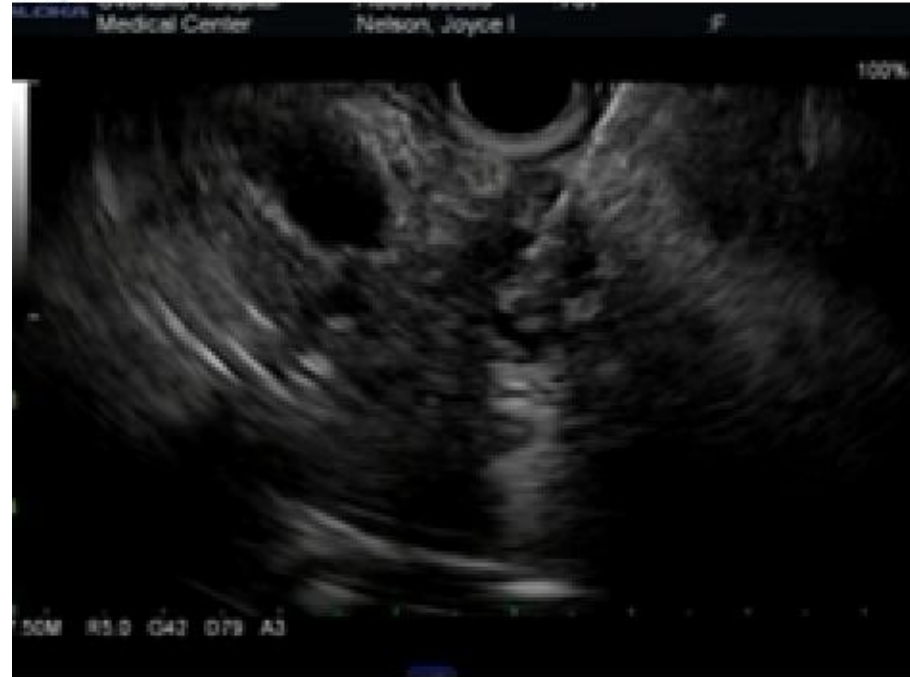- Serous cyst
 - Water filled cyst
 - Serous cystadenoma
 - Cyst CEA level <200
 - Benign condition
 - Leave it alone
- Pancreatic pseudocyst
 - Hx of pancreatitis
 - High cyst amylase level
 - Usually leave it alone



A 76 year old female with incidental finding of dilated pancreatic duct



26



- ⌞ 1.8 cm hypoechoic mass in the head of the pancreas with obstruction of the main pancreatic duct, suspicious for malignancy. Status post FNA/FNB for further evaluation.
- ⌞ Pancreatic head mass, EUS-guided fine needle aspiration:
 - Moderately cellular specimen composed of disordered mucinous epithelial clusters with mild to focally severe nuclear atypia, most consistent with at least high-grade intraductal papillary mucinous neoplasm (IPMN).

Histologic Type

Intraductal papillary mucinous neoplasm (IPMN) with associated invasive carcinoma

Histologic Grade

G2, moderately differentiated

Tumor Size

Unifocal invasive carcinoma
1.9 cm in greatest dimension

Site(s) Involved by Direct Tumor Extension

Confined to pancreas

Pancreatic Surface Involvement

Not identified

Treatment Effect

No known presurgical therapy

Lymphovascular Invasion

Not identified

Perineural Invasion

Not identified

Margin Status for Invasive Carcinoma

All margins negative for invasive carcinoma

Margin Status for Dysplasia and Intraepithelial Neoplasia

All margins negative for high-grade dysplasia
and / or high-grade intraepithelial neoplasia

Regional Lymph Node Status

Regional lymph nodes present
All regional lymph nodes negative for tumor
Number of lymph nodes examined: 18

Key takeaways

- Jaundiced patient
 - Ultrasound first, CT scan or MRI scan if dilated bile duct
 - refer to GI for ERCP and endoscopic ultrasound
- Pancreatic mass
 - endoscopic ultrasound
- Pancreatic cyst
 - endoscopic ultrasound
- Dilated pancreatic duct
 - endoscopic ultrasound
- If you have a pancreatic mass on a CT scan, don't order a MRI scan. Urgently refer to GI for endoscopic ultrasound
- How do you decide who is a surgical candidate for pancreatic cancer?
 - No metastasis
 - no arterial or venous vascular involvement
 - If there is vascular involvement, chemotherapy first to shrink the tumor and re-image