From the Weekend Warrior to the Professional Athlete:

The Evaluation, Diagnosis, and Treatment of Injuries to the Spine

Philip K. Louie, MD

Tri-Cities Pain Conference

April 29-30, 2022

Virginia Mason Franciscan Health™

No direct/relevant conflicts of interest

Royalties from textbooks which contains content discussed in this presentation:

- Elsevier
- Springer
- Thieme

About Me

Undergraduate & Medical School

UW Medicine

UW SCHOOL OF MEDICINE

Virginia Mason Franciscan Health™

Residency: Orthopaedic Surgery

MIDWEST ORTHOPAEDICS at RUSH

Fellowship: Spine Surgery

HSS HOSPITAL FOR SPECIAL SURGERY

Memorial Sloan Kettering Cancer Center

Outline

- Introduction to the topic
- **Review of cervical and lumbar radiculopathy**
- Cervical spine injuries
- Lumbar spine injuries
- **Summary of urgencies/emergencies**
- **Overview of physical exam**

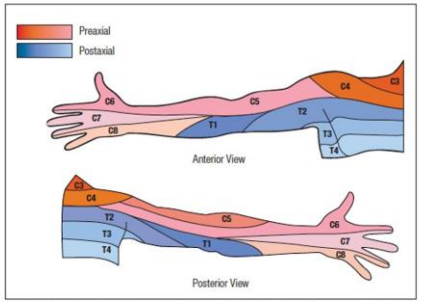

Figure 2. A map of dermatomal innervation of the shoulder and upper extremity.

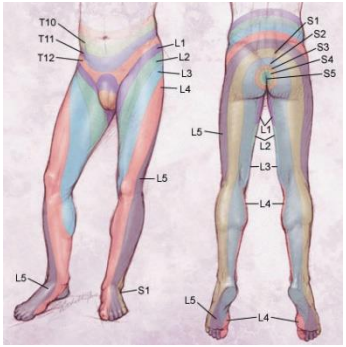

Neck and back injuries affect all ”athletes”

Virginia Mason Franciscan Health™

Even our beloved Seahawks



Virginia Mason Franciscan Health™

Lets review some helpful anatomy - CERVICAL

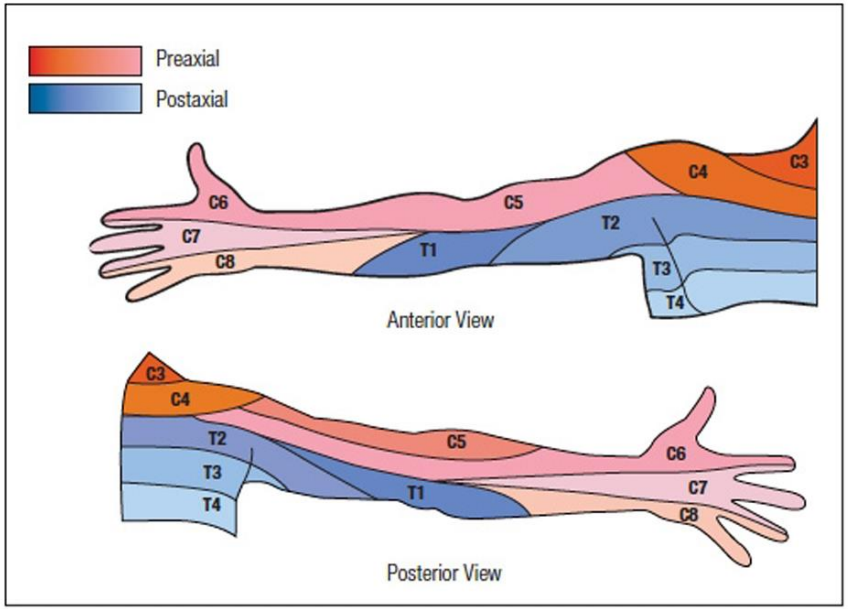

Nerve root: **C4**

Primary Motion:

Some scapular motion

Primary Muscles:

Scalenes, scapular

Sensory:

Base of neck and trapezial region

Reflex:

none

Virginia Mason Franciscan Health™

Lets review some helpful anatomy - CERVICAL

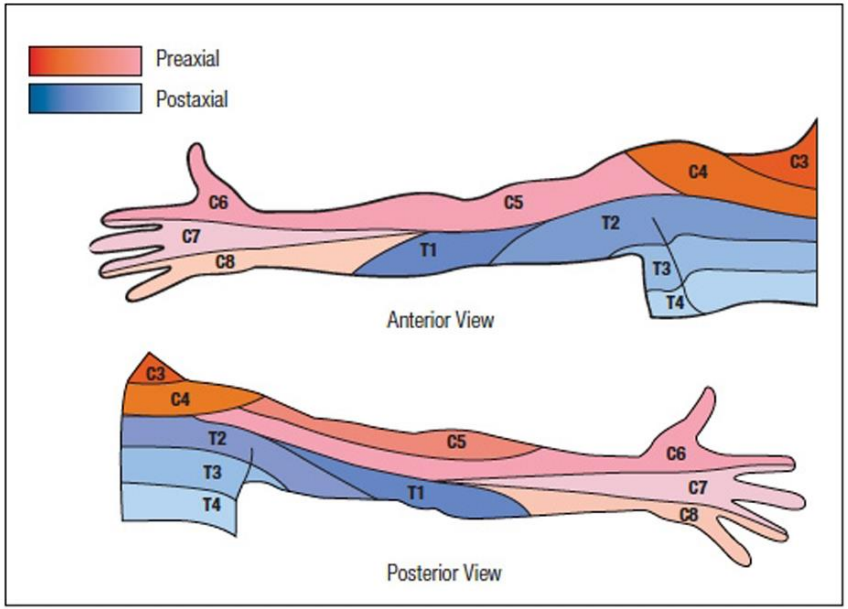

Nerve root: **C5**

Primary Motion:

Shoulder elevation/abduction

Primary Muscles:

Deltoid, some rotator cuff, biceps

Sensory:

Lateral shoulder, upper arm

Reflex:

Biceps

Virginia Mason Franciscan Health

Differentiating shoulder weakness from C5 palsy -> Can be difficult!

Good place to discuss **shoulder abduction test**

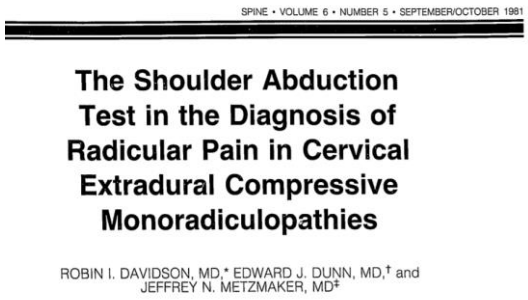
SPINE • VOLUME 6 • NUMBER 5 • SEPTEMBER/OCTOBER 1981

The Shoulder Abduction Test in the Diagnosis of Radicular Pain in Cervical Extradural Compressive Monoradiculopathies

ROBIN I. DAVIDSON, MD,* EDWARD J. DUNN, MD,† and JEFFREY N. METZMAKER, MD‡

Distance from C5 to coracoid process is reduced by shoulder abduction

Less stretch on nerve

With rotator cuff pathology pain would increase with abduction

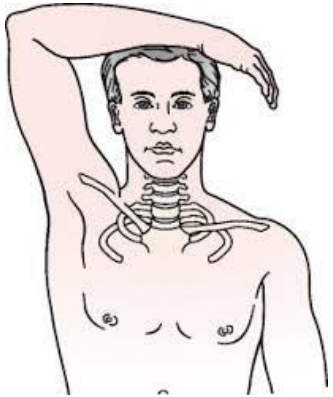

Improved pain -> **cervical** spine pathology

Worse pain -> **shoulder/rotator cuff** pathology

Virginia Mason Franciscan Health™

Lets review some helpful anatomy - CERVICAL

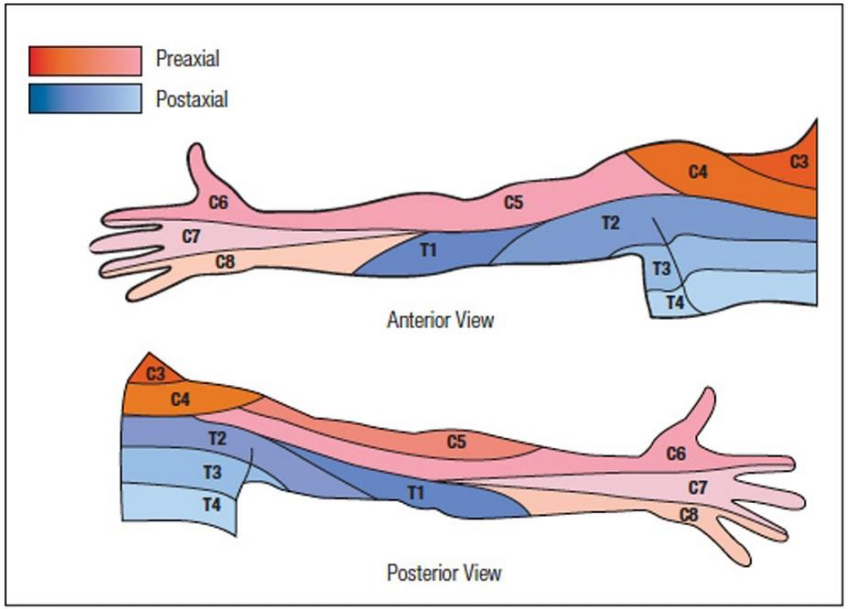

Nerve root: **C6**

Primary Motion:

Elbow flexion, Wrist extension

Primary Muscles:

Biveps, brachioradialis, wrist extensors

Sensory:

Down to the thumb/index finger

Reflex:

Brachioradialis

Virginia Mason Franciscan Health

Lets review some helpful anatomy - CERVICAL

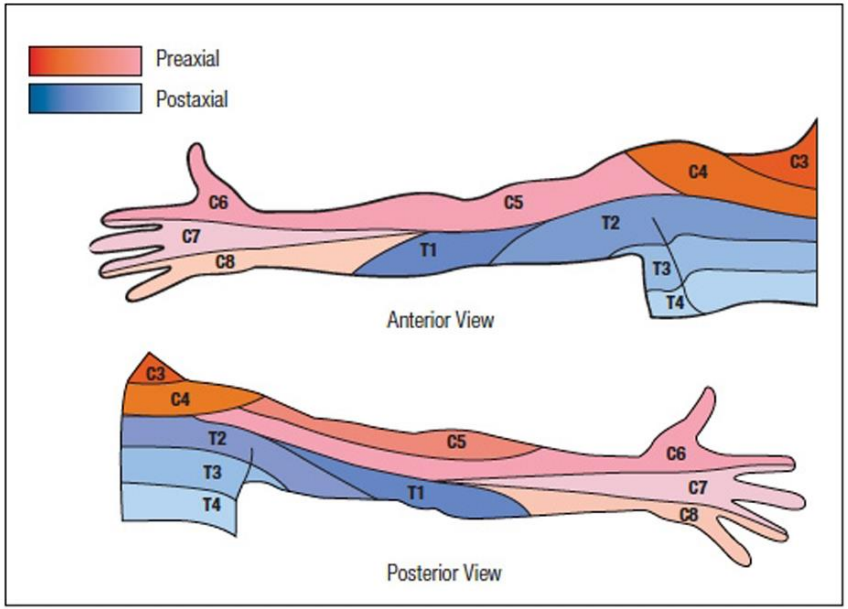

Nerve root: **C7**

Primary Motion:

Elbow extension, wrist flexion

Primary Muscles:

Triceps, wrist flexors

Sensory:

Down to the middle finger

Reflex:

Triceps

Virginia Mason Franciscan Health

Lets review some helpful anatomy - CERVICAL

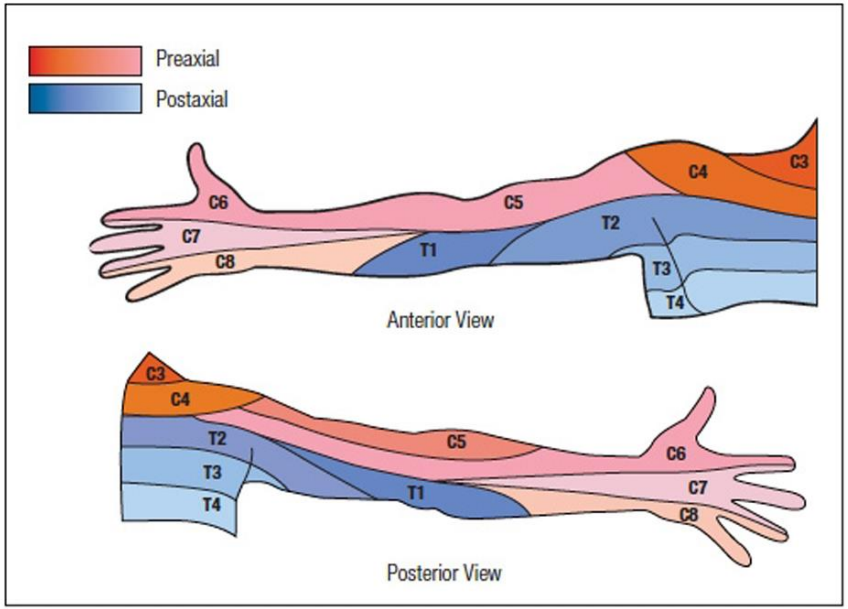

Nerve root: **C8**

Primary Motion:

Distal phalanx flexion (index/middle)

Primary Muscles:

Flexors of the digits (FDP)

Sensory:

Down to the ring/small finger

Reflex:

none

Virginia Mason Franciscan Health

Difficult to differentiate from ulnar nerve pathology

Lets review some helpful anatomy - CERVICAL

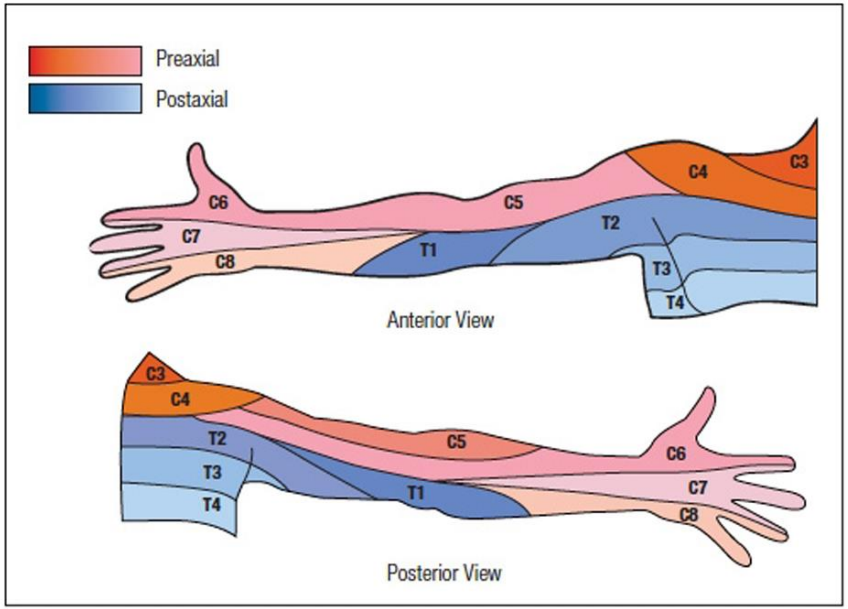

Nerve root: **T1**

Primary Motion:

Intrinsic hand muscle weakness

Primary Muscles:

Intrinsic hand muscles

Sensory:

Axillary, ulnar/medial elbow

Reflex:

none

Virginia Mason Franciscan Health

Can present with ipsilateral Horner's syndrome

Some Red Flags

- If notice that reflexes appear to be **hyper-**reflexive
- And a recent history of:
  - Gait instability (loss of coordination, frequent falls, tripping)
  - Problems with hand dexterity (difficulty buttoning buttons, handling change, tying shoelaces)
  - Numbness and tingling in hands and/or feet

Consider cervical **myelopathy (spinal cord compression)** --- *a bit more urgent!*

Virginia Mason Franciscan Health™

CERVICAL SPINE INJURIES

Cervical strain
Stinger (Burner’s syndrome)
Congenital stenosis
Herniated disc
Transient quadriplegia
~~Spear Tacklers spine~~
~~Fractures/Dislocations~~
~~Injuries to the posterior tension band (flexion-compression)~~
~~Injuries to the anterior tension band (distraction-extension)~~

Cervical Spine Injuries

- In the United States, American football, wrestling, and gymnastics are the most common sports in which cervical spine injuries are sustained.
- Cervical spine injuries are the most common injury to the axial skeleton in American football players; however, <1% of cervical spine injuries result in a cervical spine fracture or a spinal cord injury (SCI).
- Wide range from muscle/ligament strain to spinal cord injury resulting quadriparesis
- The incidence of severe injuries have dramatically decreased over the past 2-3 decades across all sporting activities due to rule changes, protective gear, and education

Virginia Mason Franciscan Health™

Cervical Strain

- Muscle strains and soft-tissue contusions are the **most common** injuries observed following sporting activity
- **Direct blows** or **rapid eccentric muscle contraction** can cause strains of the muscle.
- Presents with:
    - Localized pain without radiation or neurologic deficit
    - Range of motion limited by pain

Virginia Mason Franciscan Health

The dreaded … SPINAL CORD INJURY

Approximately **8.7% of all new cases of spinal cord injuries** in the United States are related to **sports activities**. The sports activities that have the highest risk of catastrophic spinal injuries are football, ice hockey, wrestling, diving, skiing, snowboarding, rugby, and cheerleading.

Virginia Mason Franciscan Health™

Cervical Strain

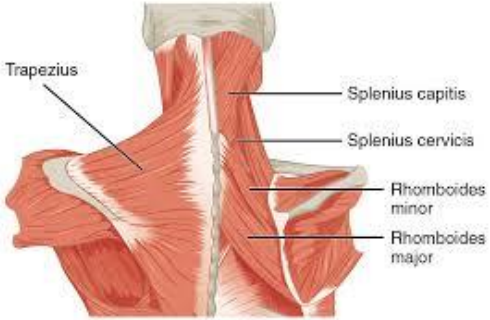

- **AP, lateral, and odontoid cervical XRs** should be obtained initially and lateral **flexion/extension** XRs can be used to assess for instability.
- Treatment: **immobilization** and **anti-inflammatories** until pain resolves.
- **Cervical neck collars/braces** can be helpful early on for the first week, but don't provide substantial benefit longer term

Cervical Strain: Return to play?



This recommendation is fairly uniform.

When **range of motion is painfree**

Virginia Mason Franciscan Health™

Stinger (Burner's syndrome)

- Sudden **pain +/- paresthesia** in a single extremity that often is nondermatomal and may or may not be associated with **weakness**
- *Transient paralysis with burning sensation that radiates from the shoulder -> fingertips*
- 3 major mechanisms of injury have been proposed:
  - **traction injury** to the **brachial plexus**
  - **direct compression** of the **brachial plexus**
  - compression of the **exiting nerve root** in the neural foramen (Torg-Pavlov ratio <0.8)

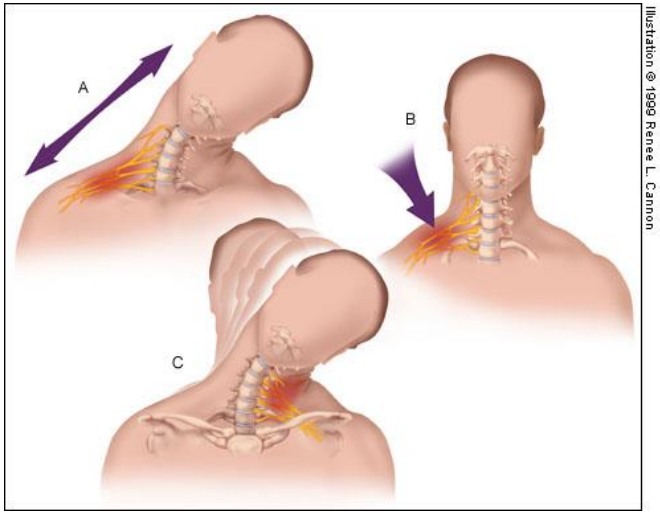

Without intervention, **symptoms should resolve in a short amount of time** (within 30 minutes).

Virginia Mason Franciscan Health

Stinger (Burner's syndrome) – Return to Play?

- Complete **resolution of symptoms** and return of **Full strength** and **full range of motion**

But…

- If **> 3 episodes within a year**; full neurologic workup; do not return to play until cleared
- If other neurologic entities are ruled out, period of **rest** and upper extremity **strength rehabilitation**

Congenital Stenosis

- Developmental narrowing (stenosis) cervical canal
- Torg-Pavlov ratio <0.8; canal diameter of < 13mm
- There is much controversy about this radiographic finding.
    - Higher risk of spinal cord injury and likely to experience temporary or permanent numbness, weakness, or paralysis if injured.
    - Not at higher risk for injury, although if injured, they are at higher risk for permanent neurologic injury, including paralysis and death.

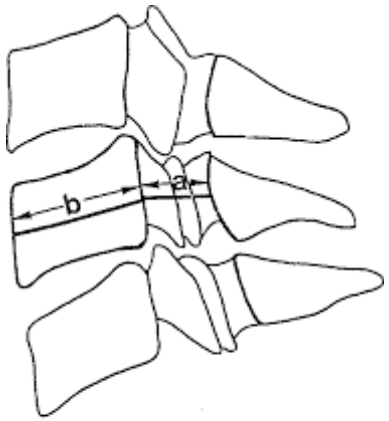

$$\text{ratio} = \frac{a}{b}$$

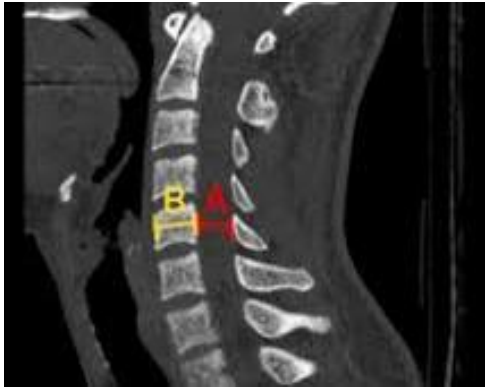

Virginia Mason Franciscan Health

Congenital Stenosis – Return to Play?

- Often not discovered until after a neck injury
- Most believe that anyone with absolute cervical spine stenosis who has even a transient neurologic deficit or sensory disturbance should seriously consider not participating in contact sports.

- In addition to permanent neurologic injury from SCI, athletes with cervical spinal stenosis also have an increased risk for cervical cord neurapraxia (transient quadriparesis).

Virginia Mason Franciscan Health

Herniated Disc

- Symptoms vary from radicular pain -> acute onset myelopathy -> transient quadriparesis
- **MRI** is gold-standard for diagnosis
- Substantial disagreement exists in the literature with regards to whether surgical or nonsurgical treatment in professional athletes who have a cervical disk herniation leads to an increased return-to-play rate, **no universally accepted treatment for isolated radicular symptoms**.
- Generally, conservative mgmt is first line for radiculopathy

Virginia Mason Franciscan Health™

It is important to remember…

The prevalence of cervical disk herniation in the asymptomatic population is variable but may be **25% for those younger than 40 years** and **60% for those older than 40 years**.

Virginia Mason Franciscan Health™

Herniated Disc – Return to Play



- Asymptomatic: okay to return to play
- In all guidelines, symptomatic disk herniation remains an absolute contraindication to athletic participation.
- If underwent discectomy and fusion (ACDF): **solid fusion**, full neck **range of motion**, and a **normal neurologic examination**
- 2-level ACDF: relative contraindication
- 3-level ACDF: absolute contraindication

Virginia Mason Franciscan Health

Transient Quadriplegia

- Pain, burning, tingling bilaterally (local compression/contusion of the spinal cord)
- Upper and/or lower extremities with variable motor deficits; can affect breathing
- Brief compression of the cord creates a ‘postconcussive’ effect on the cord
- Those with cervical stenosis may be predisposed to transient quadriplegia.
- Symptoms are temporary with complete recovery usually occurring within15 minutes, but in some recovery may take up to 48 hours

Virginia Mason Franciscan Health

Transient Quadriplegia – Return to Play

Complicated…

Based on pathology

Disc herniation: Per previous slide – Yes (possibly)

Congenital/Degenerative stenosis: NO!

Virginia Mason Franciscan Health™

How to manage if they show up in clinic?

- Neck pain
- Radicular
- Myelopathic

Virginia Mason Franciscan Health™

Neck pain

Most likely soft-tissue related: ***Cervical strain***

- **AP, lateral, and odontoid cervical XRs** should be obtained initially and lateral **flexion/extension** XRs can be used to assess for instability.
- Treatment: **immobilization** and **anti-inflammatories** until pain resolves.
- **Cervical neck collars/braces** can be helpful early on for the first week, but don’t provide substantial benefit longer term

Radicular

- 1st line: NSAIDs, steroid Medrol dose pack, physical therapy
- *Generally recommend against chiropractic care for radiculopathy*
- 2nd line: consider PM&R/physiatry consult for further management
- 2nd line: epidural steroid injection
- If presenting with **motor weakness**, 1st line algorithm can be accelerated and referral to PM&R/physiatry +/- spine surgeon
- Generally will not consider surgery unless: pain/sensory deficits and have failed a course of conservative treatment for > 6 weeks. Potentially consider surgery if motor deficit is present.

Myelopathic

Common features of clinical presentation

- Gait instability (loss of coordination, frequent falls, tripping)
- Problems with hand dexterity (difficulty buttoning buttons, handling change, tying shoelaces)
- Numbness and tingling in hands and/or feet

Myelopathic

- **History**
  - Worsening problems with balance
  - Difficulty using hands (feeling clumsy)
- **Physical Exam**
  - Difficulty walking a straight line
  - Difficulty with rapid movements of the hands
  - Hyper-active reflexes

Myelopathic

- **Hoffman's reflex or sign**
  1. Hold the middle finger extended and suddenly extend the distal interphalangeal (DIP) joint of that finger.
     - Alternative method: flick the DIP joint.
  2. Positive test: Finger and thumb flexion indicates presence of myelopathy.
- **Clonus**
  1. Rapidly dorsiflex the ankle to induce an immediate stretch of the gastrocnemius.
  2. Positive test: rhythmic, involuntary movements of the ankle more than three beats defined as sustained clonus.
- **Babinski reflex**
  1. Gentle stimulus applied to the lateral aspect of the sole of the foot, starting over the heel extending towards the 5th digit normally results flexion of toes.
  2. Positive test: initial dorsiflexion of the great toe and spreading of the other toes.

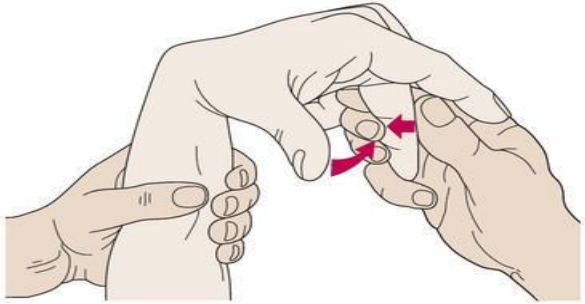

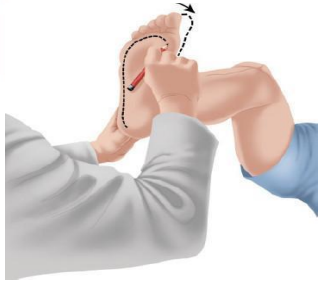

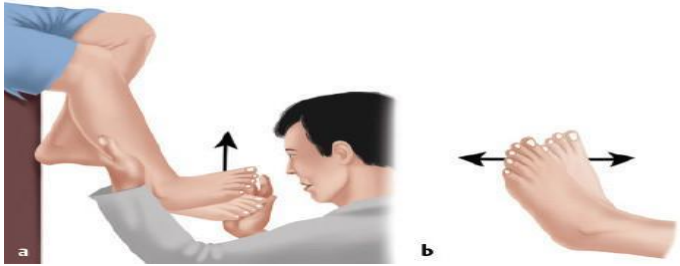

Myelopathic

Grip and release test

Patients make a fist and release 20 times in 10 seconds.

Positive test: inability to complete this task in 10 seconds is indicative of myelopathy.

Inverted brachioradialis reflex

Tapping of the distal brachioradialis tendon produces spastic ipsilateral finger flexion instead of the normal extension of the wrist.

Positive test: positive reflex suggests spinal cord compression at the C6 region.

Pronator Drift

Patients hold hands in front of them and spread their fingers apart and close their eyes

Positive test: one arm will drift down and pronate within 10 seconds which would suggest upper motor neuron weakness.

Romberg Sign

Patient stands with arms held forward and eyes closed

Positive test: loss of balance consistent with posterior column dysfunction

Myelopathic

Cervical spine MRI

TREATMENT OPTIONS

- Non-operative treatment
  - Observation (only in very mild cases)
- Operative treatment
  - Only way to take pressure off the spinal cord is with surgery
  - There are MANY different ways to do this

Virginia Mason Franciscan Health™

LUMBAR SPINE INJURIES

Lumbar strain
DDD
HNP
Cauda Equina
Spondylolysis
~~Fractures~~

Virginia Mason Franciscan Health™

Lets review some helpful anatomy - LUMBAR

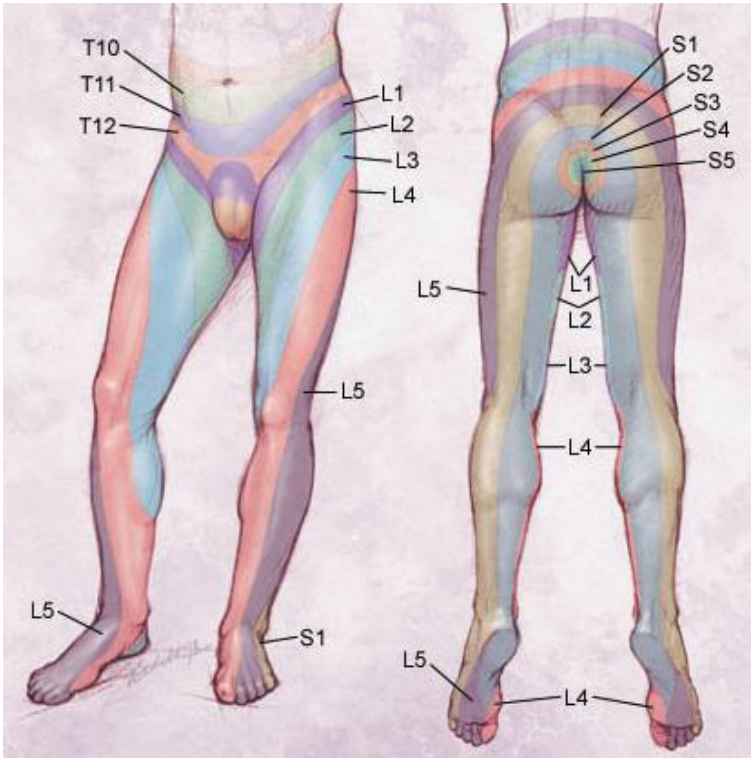

Nerve root: **L2,3**

Primary Motion:

Hip Flexion, Hip adduction

Primary Muscles:

Iliopsoas, Hip adductors

Sensory:

Anterior and inner thigh/groin

Reflex:

None

Virginia Mason Franciscan Health

Lets review some helpful anatomy - LUMBAR

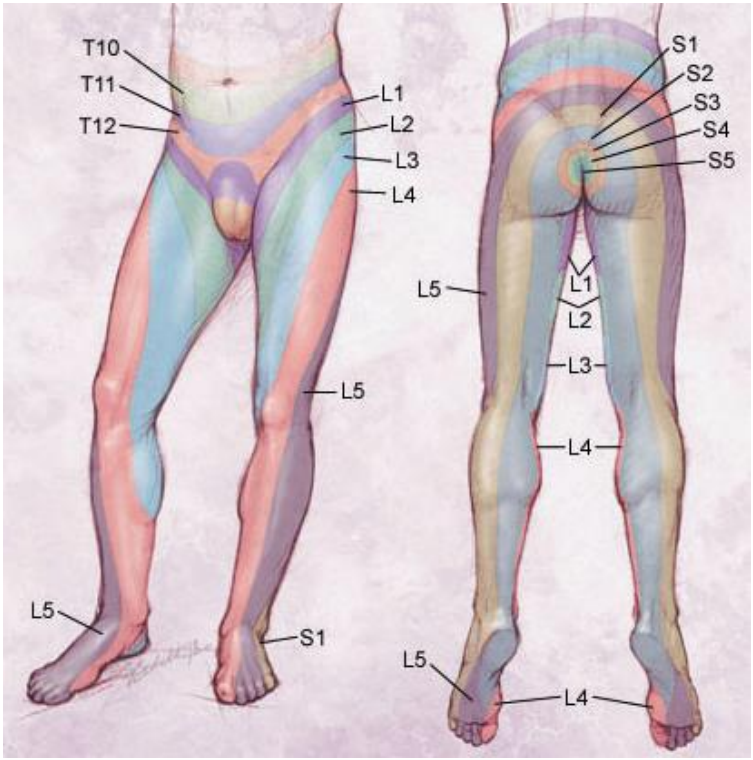

Nerve root: **L4**

Primary Motion:

Knee Extension (+L3)

Ankle Dorsiflexion (+L5)

Primary Muscles:

Quadriceps

Sensory:

Anterolateral thigh, anterior knee, medial lower leg

Reflex:

Patellar

Virginia Mason Franciscan Health™

Lets review some helpful anatomy - LUMBAR

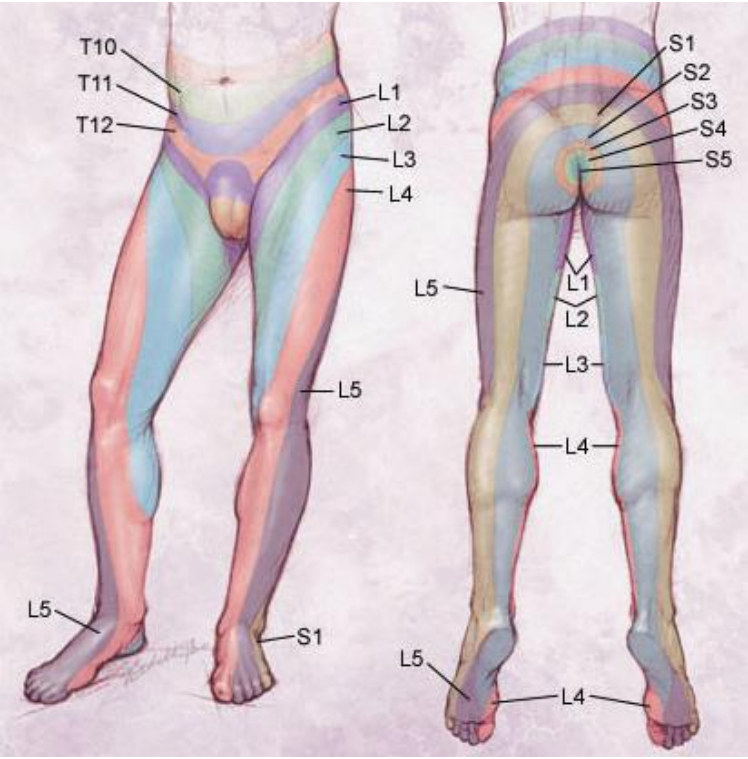

Nerve root: **L5**

Primary Motion:
Ankle Dorsiflexion (+L4)
Toe Dorsiflexion
Hip extension/abduction
Foot inversion

Primary Muscles:
Tibialis anterior/posterior
EHL/EDL (Toes)
Hamstrings
Gluteal muscles

Sensory:
Lateral thigh, lateral lower leg, dorsum foot

Reflex:
None

Virginia Mason Franciscan Health

Lets review some helpful anatomy - LUMBAR

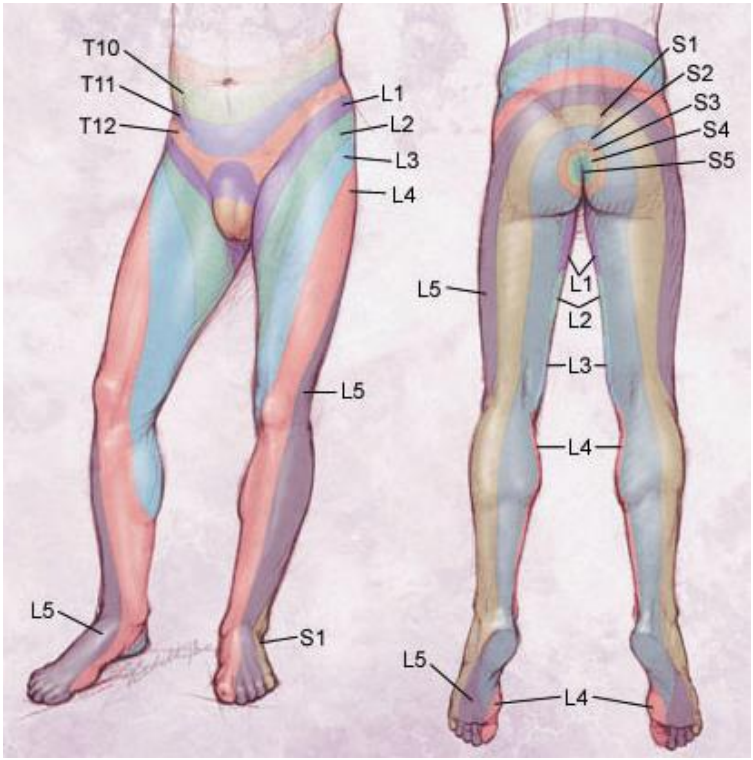

Nerve root: **S1**

Primary Motion:

Ankle plantarflexion & eversion

Primary Muscles:

Gastroc-soleus

Peroneals

Sensory:

Posterior thigh, lower leg

Plantar foot

Reflex:

Achilles

Virginia Mason Franciscan Health

Lumbar strain

- Injury in the lower back where the **ligaments, tendons or muscles** have been over-stretched/pulled.
- Wide range of symptoms:
  - Sudden lower back pain
  - Spasms
  - Sore to deep palpation

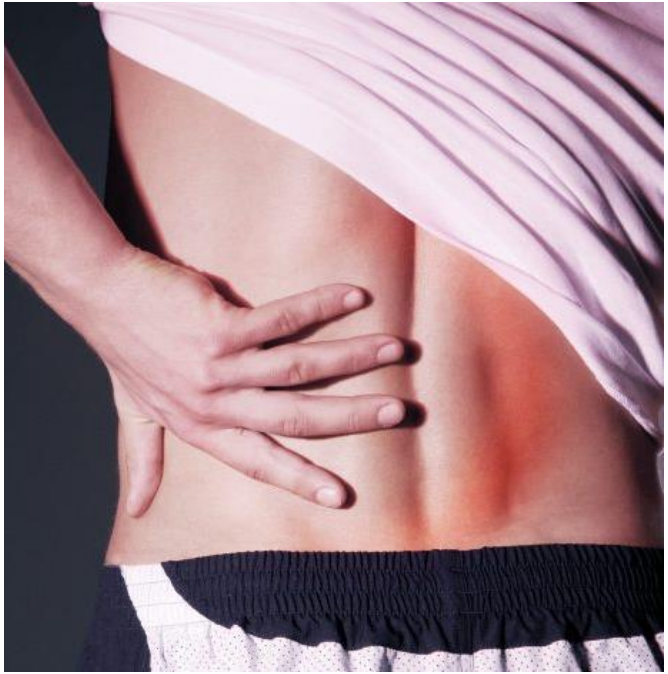

Virginia Mason Franciscan Health™

Lumbar strain

<u>Workup</u>

- **History** – most important
- Physical exam
  - *Pain with palpation of muscles / soft tissues*
- Xrays (*questionable*)
  - *To rule out additional injury*
- MRI usually not necessary
  - *If no concerning neurologic symptoms*

Lumbar strain

<u>Treatment</u>

- Rest/Short period of immobilization
- **want to be active & avoid bedrest**
- Anti-inflammatories (ibuprofen, naproxen)
- Muscle relaxers
- Ice or heat (whichever feels better)
- Massage
- Stretching
- Physical therapy and regular aerobic exercise

Operative treatment “never” necessary!

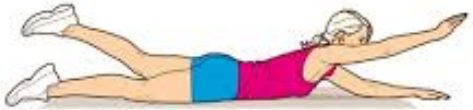

Proper Lifting

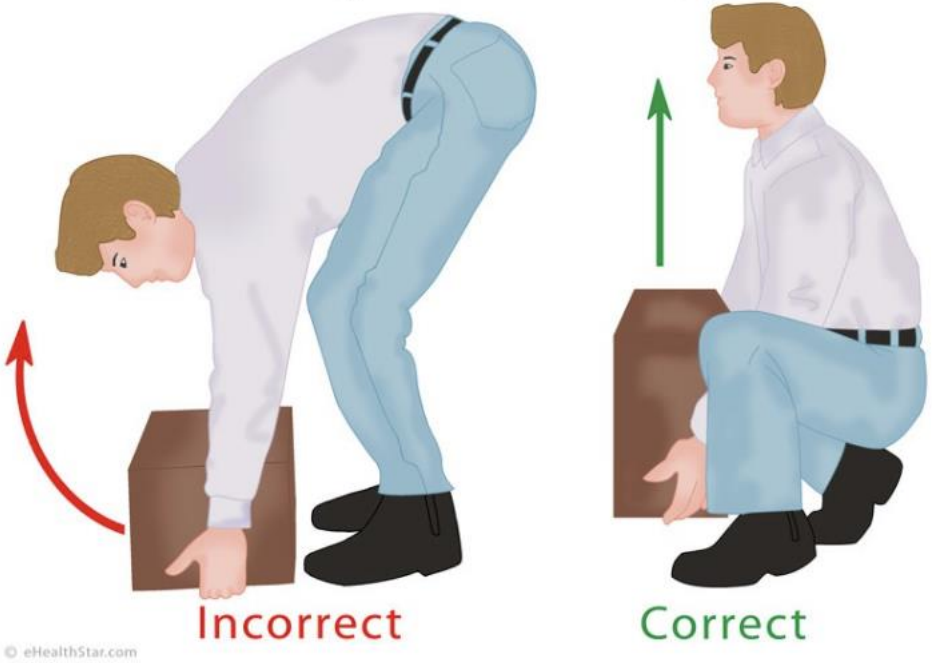

Virginia Mason Franciscan Health™

Lumbar strain – Return to Play



Can return to full activities when **symptoms subside** and **full range of motion** is regained



Virginia Mason Franciscan Health™

Degenerative Disc Disease (DDD) – Flare Up

- **Moderate, continuous low back pain.** Pain may spread to the buttocks, groin, and upper thighs. This pain typically feels achy, dull, and can range from mild to severe.
- **Occasional pain flare-ups.** Back pain may intensify for several days or weeks then return to a more moderate level. Flare-ups happen as the disc continues to degenerate and the spine gradually stabilizes.
- **Local tenderness.** Local soreness is caused by inflammation and muscle tension surrounding the degenerated disc.
- **Leg pain.** Neurological symptoms including numbness, weakness, or sharp, shooting pains in the buttocks, hips, and/or back of the leg may be felt if the disc space collapses enough to pinch a nerve root exiting the spine.
- **Giving out symptoms.** A feeling of sudden weakness or instability can happen as the disc becomes weaker, creating a sensation that the low back will “give out” with sudden movements.

Degenerative Disc Disease

- Complex interplay between **environmental** and **genetic** factors
- **Decrease in nutrient supply**
  - Negatively impacts the disc maintaining the ECM
  - Limits ability of the disc to respond to load or injury
- **Genetic** Factors
  - Twin studies show that up to 70% of DDD linked to genetics
  - Polymorphisms affect genes which contribute to IVD structure, catabolic pathways and pro-inflammatory pathways
- **Environmental** Factors
  - **Obesity**: BMI>25 risks factor for radiographic DDD at young age
  - **Cigarettes:** Decreased blood flow at the vertebral endplate, activation of muscarinic receptors located at the endplate, twin studies show powerful negative effect of cigs

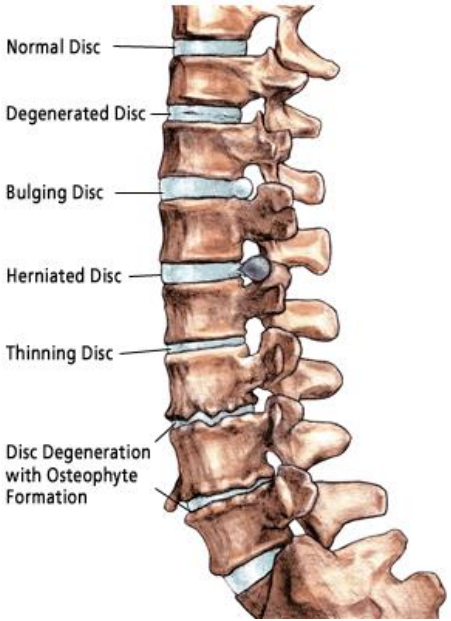

Virginia Mason Franciscan Health

Degenerative Disc Disease

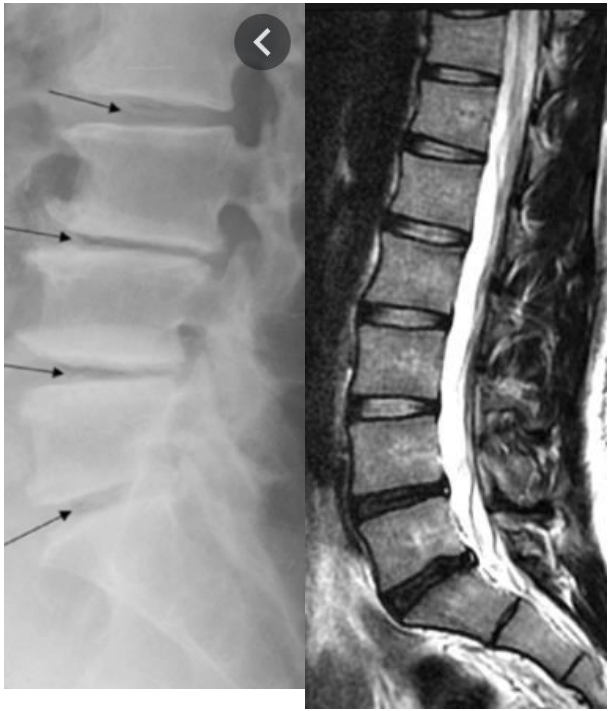

- History and Physical exam may be vague
  - Ultimately, ruling out other etiologies of symptoms
- **X-rays:** These can show a decrease in disc height or bone spurs (osteophytes), rule out other osseous pathology
- **MRI:** generally confirms disc degeneration (“black disc” on T2); assess for neurologic involvement
- **CT:** not indicated, unless unable to obtain MRI (if necessary)

Degenerative Disc Disease

Essentially all non-operative!

Physical Therapy

Medications: NSAIDs, muscle relaxants

Lifestyle modification

- Smoking Cessation
- Weight loss

CBT

Yoga?

Alternative Pain Medications

- CBD?

Virginia Mason Franciscan Health

Degenerative Disc Disease

International Orthopaedics (SICOT) (2017) 41:2097–2103
DOI 10.1007/s00264-017-3560-9

CrossMark

ORIGINAL PAPER

Autologous bone marrow concentrate intradiscal injection for the treatment of degenerative disc disease with three-year follow-up

Kenneth A. Pettine[1] · Richard K. Suzuki[2] · Theodore T. Sand[2] · Matthew B. Murphy[2,3]

Review Article

Stem Cell Therapy for Degenerative Disc Disease

Doniel Drazin,[1] Jack Rosner,[1] Pablo Avalos,[2] and Frank Acosta[1]

[1] *Department of Neurosurgery, Cedars-Sinai Medical Center, Los Angeles, CA 90048, USA*
[2] *Regenerative Medicine Institute, Cedars-Sinai Medical Center, Los Angeles, CA 90048, USA*

Eur Spine J (2008) 17 (Suppl 4):S441–S451
DOI 10.1007/s00586-008-0749-z

REVIEW

Biological repair of the degenerated intervertebral disc by the injection of growth factors

Koichi Masuda

Can't we just re-grow the disc?

Humans: NO!

Animals: ??

ELSEVIER

The Spine Journal
Volume 14, Issue 6, 1 June 2014, Pages 1017-1028

Basic Science

Intradiscal injection of simvastatin results in radiologic, histologic, and genetic evidence of disc regeneration in a rat model of degenerative disc disease

Khoi D. Than MD [a], Shayan U. Rahman MD [a], Lin Wang MD [a], Adam Khan BA [b], Kwaku A. Kyere BA [b], Tracey T. Than [a], Yoshinari Miyata PhD [a], Yoon-Shin Park PhD [c], Frank La Marca MD [a], Hyungjin M. Kim ScD [d], Huina Zhang MD, PhD [a], Paul Park MD [a], Chia-Ying Lin PhD [a]

13–18

Platelet-rich plasma effects on degenerative disc disease: analysis of histology and imaging in an animal model

Authors Gregory B Gullung[1], James W Woodall[1], Michelle A Tucci[1], Judy James[2], David A Black[1], Robert A McGuire[1]

Institutions [1] Department of Orthopaedics, University of Mississippi Medical Center, Jackson, MS, USA
[2] Department of Radiology, University of Mississippi Medical Center, Jackson, MS, USA

Stem Cells and Development, Vol. 15, No. 1 | Case Report

Full Access

Intradiscal Injection of Hematopoietic Stem Cells in an Attempt to Rejuvenate the Intervertebral Discs

Dr. Scott M.W. Haufe and Anthony R. Mork

Virginia Mason Franciscan Health™

Degenerative Disc Disease – Return to Play

Can return to full activities when **symptoms subside** and **full range of motion** is regained.

Virginia Mason Franciscan Health™

Herniated Disc

General Symptoms:

- Back pain (discogenic vs. degenerative)
- Referred buttock pain
- Leg pain (often unilateral)
- Pain **worsened w/ flexion**
- Weakness
- Bladder disturbances
    - recurrent UTI present in up to 10% due to autonomic sphincter dysfunction

Herniated Disc

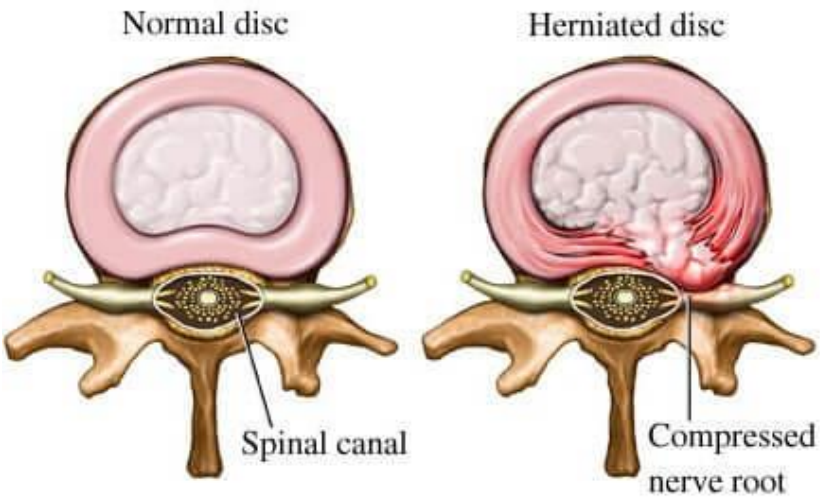

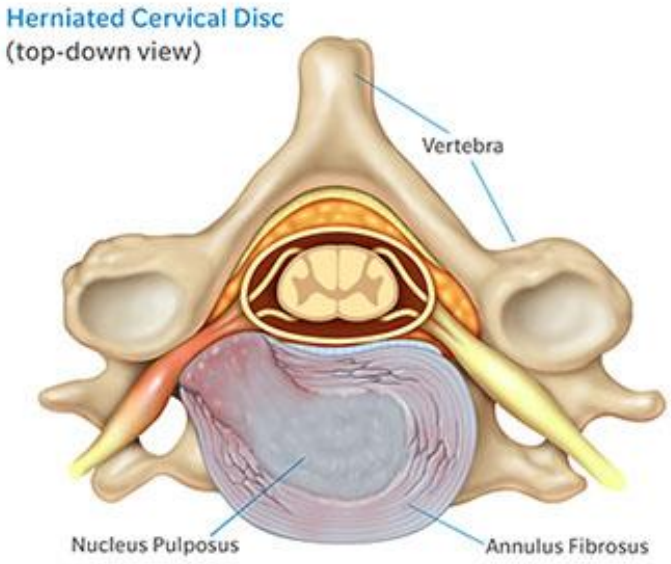

Herniated disc

https://healthcareextreme.com/

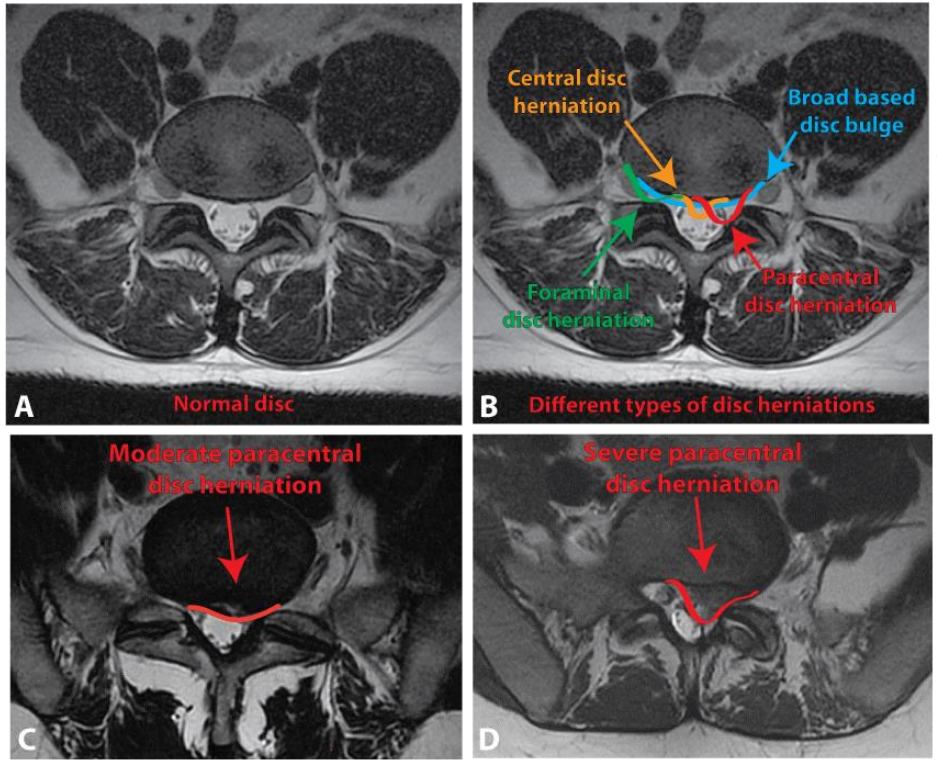

The progressive degeneration of a disc, or traumatic event, can lead to a failure of the annulus to adequately contain the nucleus pulposus

This is known as herniated nucleus pulposus (HNP) or a herniated disc

Virginia Mason Franciscan Health

Herniated disc

- **Back flexion vs. Extension** (Kemp test)
  - Herniated disc: worse back pain and radicular symptoms in flexion
  - Degenerative stenosis: worse back pain and radicular symptoms in extension
- **Straight leg raise** (tension sign) – seated or supine
  - Herniated disc: may reproduce leg symptoms 30-70 deg of hip flexion
  - Degenerative stenosis: no impact on symptoms
- **Valsalva**
  - Herniated disc: may reproduce leg symptoms
  - Degenerative stenosis: no impact on symptoms

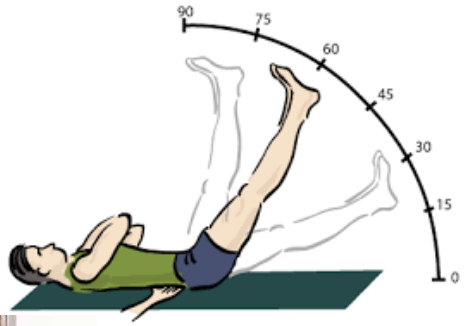

Virginia Mason Franciscan Health

Herniated Disc

1st line: rest, physical therapy, anti-inflammatory medications

- **85%** of lumbar disc herniations improve w/out surgery 6 weeks-3 months

- Medications: NSAIDS, steroid taper pack, +/- muscle relaxer
- Physical Therapy: extension-based exercises, +/- traction, +/- chiropracter

2nd line: steroid injections

- When medications/therapy fails
- I like to wait at least 6 weeks
- Results are incredibly variable

Virginia Mason Franciscan Health

Herniated Disc

In general, there are 2 forms of surgery:

(can be performed open or with minimally-invasive techniques)

1) Decompression-only
    1) Discectomy/Microdiscectomy
    2) Laminectomy/Laminotomy
2) Decompression + fusion
    1) Indications vary --- but need to correlate symptoms with specific anatomic features (instability, orientation of facet joints, amount of foraminal collapse, etc…)

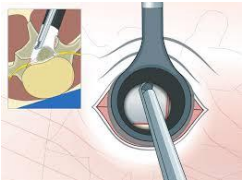

I want to re-iterate one more time…

BLACK DISCS ARE NOT AN INDICATION FOR SURGERY!!

Virginia Mason Franciscan Health™

Herniated Disc – Return to Play



This varies widely, although most can return to full activities within 6-8 weeks.

If no surgery: similar protocol to previous conditions

If surgery (discectomy): often 6-8 weeks

Virginia Mason Franciscan Health™

Spondylolysis

Spondylolysis

- Common source of back pain in adolescent population
- Complete **fracture of the pars interarticularis**
- Risk factors and causes vary widely
- Oblique XRs or CT scan helpful
- 15% will progress to *spondylolisthesis*
- Most younger patients improve without surgical intervention
- Surgery: pars repair, fusion

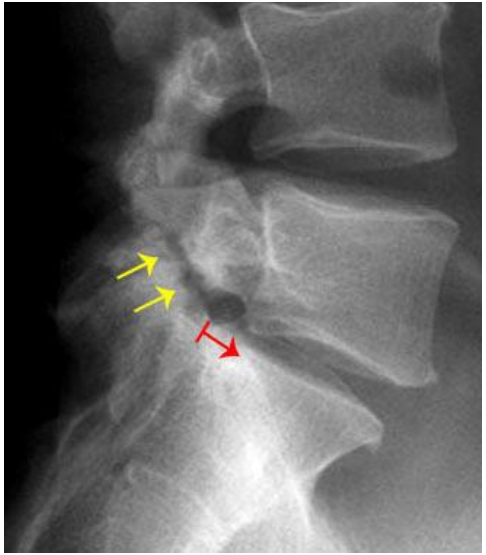

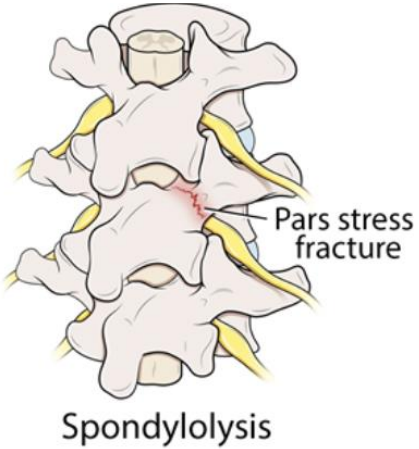

Virginia Mason Franciscan Health

Spondylosis – Return to Play

- For the **conservative treatment** of lumbar spondylolysis, some investigators recommend between **4 and 12 weeks of rest and immobilization**
- At **6–12 months after a pars repair**, return to play at pre-injury level is possible, but after **fusion for spondylolysis and spondylolisthesis there is a less predictable course of returning to contact sports**.



Virginia Mason Franciscan Health™

Emergency/Urgency

“I’m having difficulty controlling my bladder”

“I just pooped, and I didn’t really notice it”

Cauda Equina Syndrome?

Virginia Mason Franciscan Health™

Cauda Equina Syndrome

- Cauda equina syndrome is caused by ***severe compression*** of the nerve roots in the thecal sac of the lumbar spine, <u>most commonly due to an acute lumbar disc herniation</u>
- Presumptive diagnosis is made by characteristic presenting symptoms:
    - saddle-like paresthesias
    - Loss of bladder/bowel function
    - Progressive weakness in the lower extremities
- confirmed with emergent MRI.
- Treatment involves **<u>surgical decompression within 48 hours</u>**

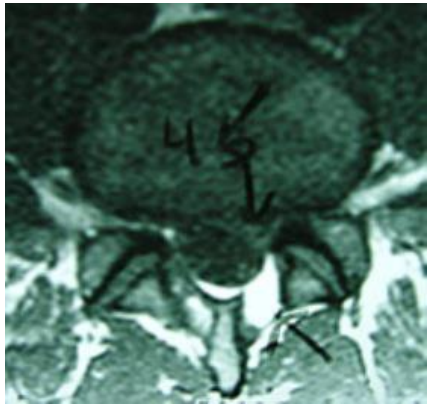

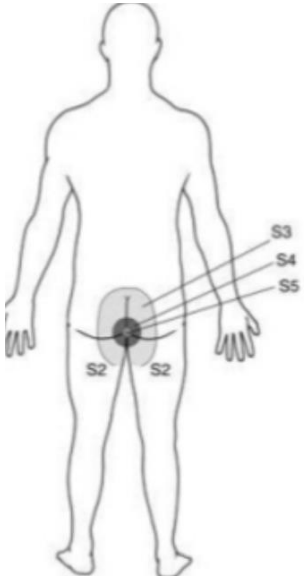

Virginia Mason Franciscan Health

Cauda Equina Syndrome

Why is it so important to catch this early?

- studies have shown improved outcomes in bowel and bladder function and resolution of motor and sensory deficits when decompression **performed within 48 hours of the onset of symptoms**
- residual bladder deficits may persist despite successful decompression
- bladder function may continue to improve up to 16 months post-op
- motor recovery may continue up to 1 year post-op

One more time … watch for Cervical Myelopathy

- **“I’m having problems with my balance”**
  - Gait instability (loss of coordination, frequent falls, tripping)
- **“My hands and fingers don’t feel like they are working like normal”**
  - Problems with hand dexterity (difficulty buttoning buttons, handling change, tying shoelaces)
- “**I feel numbness/tingling in everywhere”**
  - Numbness and tingling in hands and/or feet

Cervical Myelopathy

- **History**
  - Worsening problems with balance
  - Difficulty using hands (feeling clumsy)

- **Physical Exam**
  - Difficulty walking a straight line
  - Difficulty with rapid movements of the hands
  - Hyper-active reflexes

Check a **cervical and/or thoracic spine MRI** – assess for spinal cord compression that may be otherwise asymptomatc

Virginia Mason Franciscan Health™

Spine Physical Exam

Overall Plan for Spine Exam:

1) Inspection
2) Palpation
3) Movement
4) Neurologic examination
    - Sensory
    - Motor
    - Reflexes
5) Special Tests

Thank you.

Questions?

Philip.louie@vmfh.org

Office #: (206)341-0561

Cell #: (253)906-9256

Virginia Mason Franciscan Health